

# Cantilever Bending Technique for Treatment of Large and Rigid Scoliosis

Kao-Wha Chang, MD

**Study Design.** Retrospective review of a consecutive clinical series.

**Objectives.** To assess the efficacy and clinical value of cantilever bending technique as a technique for correcting large ( $\geq 70^\circ$ ) and rigid (flexibility  $\leq 30\%$ ) scoliosis.

**Summary of Background Data.** Scoliosis correction by current methods is a compromise between the rigidity of the deformity and corrective forces provided by these methods. For large and rigid scoliosis, the rigidity of the deformity cannot be overcome enough to achieve satisfactory correction. Thus, anterior release procedures are usually necessary to make the curves more flexible and thus improve correction. The cantilever bending technique provides powerful corrective forces for overcoming the rigidity of the deformity and obviates the need for anterior release procedures. The utility and efficacy of the method alone without anterior release for treating large and rigid deformity has not been demonstrated.

**Methods.** A total of 41 consecutive patients undergoing cantilever bending technique for the management of large and rigid scoliosis of any etiology (congenital, idiopathic, or neuromuscular) were included. Radiographic studies, complications, and satisfaction assessment using the modified Scoliosis Research Society Instrument were used to assess outcomes.

**Results.** The mean Cobb angle of the major curves was  $98^\circ$  (range  $75\text{--}133^\circ$ ). The deformity correction was 67.1% (range 51–74%). Coronal imbalance was 2.5 cm before and 0.8 cm after surgery. No major complication occurred. Satisfactory correction was achieved in all patients and without anterior release in all but one patient. Regardless of the etiology of their deformities, all patients were very satisfied with their outcomes.

**Conclusions.** The cantilever bending technique is an effective procedure for the management of large and rigid scoliosis regardless of etiology. The clinical value of the procedure was demonstrated by reduced need for anterior release, fewer complications, and high rates of patient satisfaction. [Key words: anterior release procedures, large and rigid scoliosis, cantilever bending technique] *Spine* 2003;28:2452–2458

physician. Currently, scoliosis is usually corrected by a rod derotation maneuver,<sup>1</sup> vertebra-to-rod method, or three-rod technique, depending on the pathology of the patient. Correction by these methods is a compromise between the rigidity of the deformity and corrective forces provided by these methods. For large and rigid scoliosis, the rigidity of the deformity cannot be overcome enough by the corrective forces to achieve satisfactory correction. So, an anterior release procedure is almost always needed to make the curves more flexible and thus to improve correction.

In this study, the cantilever bending technique alone without anterior release was tried to correct large and rigid scoliosis. The superior biomechanical advantages of the method provide the surgeon with powerful correctives for overcoming the rigidity of the deformity and thus avoid the use of anterior release procedures.

The efficacy of a method in correcting deformity can be assessed by radiographic parameters and absolute correction. The clinical value of the method is best assessed by measurement of complications and patient satisfaction. This article will review the efficacy and clinical value of cantilever bending technique in the treatment of patients with large and rigid scoliosis.

## Materials and Methods

Before 1998, the major indication for additional anterior release was large ( $\geq 70^\circ$ ) and rigid curvature ( $\leq 30\%$  compensation on best-effort supine side-bending radiographs). Anterior surgery was necessary to make the curves more flexible and thus improve correction. Since 1998, the author has been trying to use the cantilever bending technique alone without anterior release for management of large and rigid scoliosis. He has used the procedure in 73 patients. In total, 41 patients, followed for 2 or more years after surgery, are included in this report. Preoperative and postoperative radiographic evaluation included standing posterior-anterior (PA) and lateral radiographs and best-effort supine side-bending radiographs. The PA radiograph and side-bending films were examined, and a number of parameters were recorded. Cobb angles of the major curve and the compensatory curve were needed to determine flexibility and correction. Correction/flexibility (C/F) was calculated to determine the correction in cases of excess side-bending flexibility. From the lateral radiographs, Cobb angles from T4 to T12 were obtained to measure gross thoracic kyphosis and from L1 to L5 to measure gross lumbar lordosis. The junctional kyphosis between curves was noted.

Coronal balance was assessed on the PA radiographs by measuring the deviation of the C7 plumb line from the median sacral line. Comparisons between the pre- and postoperative measures of balance were made.

Clinical outcome was assessed using: 1) a detailed retrospective review of records (including inpatient and outpatient

The correction of large and rigid scoliosis is a contemporary and challenging subject for the spinal deformity

From the Department of Orthopaedic Surgery, Armed Forces Taichung General Hospital, Taiping City, Taichung Hsein, Taiwan, Republic of China.

Acknowledgment date: June 21, 2002. First revision date: September 16, 2002. Second revision date: December 11, 2002. Acceptance date: March 4, 2003.

The manuscript submitted does not contain information about medical device(s)/drug(s).

No funds were received in support of this work. No benefits in any form have been or will be received from a commercial party related directly or indirectly to the subject of this manuscript.

Address correspondence to Kao-Wha Chang, MD, Department of Orthopaedic Surgery, Armed Forces Taichung General Hospital, No. 348, Sec. 2, Chung-Shan Road, Taiping City, Taichung Hsein, Taiwan, Republic of China; E-mail: iscpine@ms45.url.com.tw

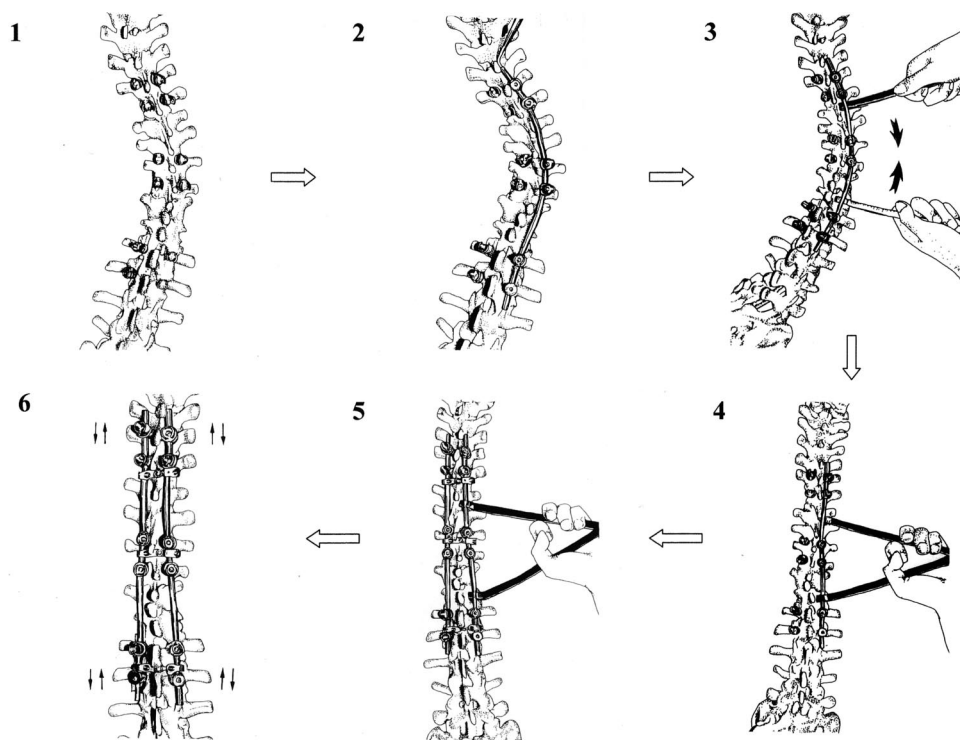


Figure 1. Cantilever Bending Technique 1. Insert 6 groups of pedicle screws. 2. Lock the convex rod to pedicle screws. 3. Secure *in situ* binders to the convex rod. 4. Cantilever bending to correct scoliosis. 5. Secure the concave rod to the pedicle screws and establish the transverse links. 6. End vertebrae adjustment and remove the *in situ* binders.

charts) to determine perioperative and long-term complications; and 2) a disease-specific outcomes questionnaire.<sup>2,3</sup> A patient-based evaluation of outcome was collected using the modified Scoliosis Research Society patient satisfaction domain measurement tool. This self-assessment of outcome provides useful information for evaluation of the clinical value of the cantilever bending technique.

**Surgical Techniques.** In patients undergoing surgical correction, six groups of pedicle screws were inserted on the upper, apical, and lower segments on both sides of a curve (Figure 1, part 1). After the pedicle screw was positioned, a prebent rod was locked to the pedicle screws on the convex side (Figure 1, part 2). As two lever arms in the coronal plane, two long *in situ* binders were secured to the convex side of the rod (above and below the attachment of the apical pedicle screws) in the coronal plane (Figure 1, part 3). Bringing the free ends of the lever arms closer to each other could generate a powerful corrective force to correct the curve in the coronal plane (Figure 1, part 4). If necessary, another two long *in situ* binders were secured to the rod above and below the attachment of apical pedicle screws in the sagittal plane and acted as two lever arms in the sagittal plane. These can correct deformity in the sagittal plane with separate application of corrective force by the cantilever bending technique. A rod prebent to conform to the corrected curve was secured to the screws on the concave side to support and maintain the corrected curvature (Figure 1, part 5). After connecting both rods by transverse links and finely adjusting the end vertebrae according to the intraoperative PA radiographs to balance the body, the lever arms were released (Figure 1, part 6). The *in situ* binders were not removed until the corrected curvature was rigidly fixed.

## Results

Forty-one consecutive patients (29 female and 12 male) who were followed up for a minimum of 2 years are

included in this study. Their average age was 31.1 years (range 11–61 years). Follow-up was 35.5 months (range 24–52 months). The etiologic diagnosis was idiopathic scoliosis in 26, congenital kyphoscoliosis in 7, and neuromuscular scoliosis in 8 patients. The mean Cobb angle of the major curve was 98° (range 75–133°). Preoperative flexibility of the major curve averaged 18% (range 2–27%). Correction of major curve averaged 67.1% (range 51–74%) and was definitely much more than the flexibility. The ratio (correction/flexibility) of major curve averaged 3.7 (range 2.1–28). In 12 patients with preoperative thoracic hypokyphosis (gross kyphosis less than 15°), there were significant improvements. The mean preoperative hypokyphosis of 7° was corrected to a mean of 29°, showing almost normal thoracic kyphosis. Thirty patients had thoracolumbar kyphosis. All were effectively corrected by sagittal lordotic leverage at the kyphosis, and there was an average improvement of 24° from a preoperative mean of 34° to a postoperative mean of 10°. In 11 patients with preoperative lumbar kyphosis, there were significant improvements. The mean preoperative kyphosis of 18° (range 1–31°) was corrected to -13° (range -33–7°). Preoperative coronal imbalance was observed in 23 of the 41 patients. Average coronal offset in these patients was 2.5 cm before surgery, 0.7 cm after surgery, and 0.8 cm at the most recent follow-up (Table 1).

Clinical outcome was assessed using the modified Scoliosis Research Society instrument. Of 41 patients, 38 were extremely satisfied with their management, 3 were somewhat satisfied, and no patient was dissatisfied. Furthermore, 39 patients would definitely repeat their sur-

**Table 1. Deformity Correction in 41 Patients**

Deformity	No. of Patients	Preoperative	Postoperative	Correction
Scoliosis	41	98°	32.2°	67.1%
Thoracic hypokyphosis	12	7°	29°	22°
Thoracolumbar kyphosis	30	34°	10°	24°
Lumbar kyphosis	11	18°	-13°	31°
Coronal imbalance	23	2.5 cm	0.7 cm	1.8 cm

ger and 2 would probably repeat surgery. Postoperative satisfaction scores averaged 95% (Table 2).

There were no neurologic complications. There was a hemothorax in one patient with idiopathic scoliosis. This complication was due to segmental vessel injury during preparation of a screw hole. She was treated by insertion of a chest tube, which was removed 2 weeks later. In one patient with a King II curve, the lumbar curvature increased after thoracic curvature correction and was revised by distal extension of the correction and fusion. There was one superficial infection, which was treated by incision and drainage. The infection healed uneventfully.

There was one patient whose scoliosis was too rigid to obtain satisfactory correction by this method and also needed anterior release. All other patients achieved satisfactory correction from the cantilever bending technique alone. In this patient, the deformity was too rigid to be corrected by cantilever bending technique even after extensive posterior release and partial facetectomy. The wound was temporarily closed, and the patient was repositioned in lateral decubitus position to perform anterior release. When that was completed, the patient was then return to prone position, and the deformity was corrected by cantilever bending technique.

#### Case Example

A case example is shown in Figure 2. This 24-year-old female, who presented with idiopathic scoliosis, had a very large right thoracic curve of 110°. The patient was well balanced. Her C7 was centered on the sacrum. The major curve was very rigid with a flexibility of 4.5%. Postoperative standing radiographs of the patient show a correction of 59% and good balance. The ratio of correction/flexibility was 13 (Figure 2A). The patient is extremely satisfied with the ultimate clinical appearance. She gained 10 cm in trunk height (Figure 2B).

A second case example is shown in Figure 3. This 19-year-old male, who presented with congenital scoliosis, had a 117° right thoracolumbar curve. The patient's trunk was significantly decompensated to the right. His

C7 fell well to the right of the midline of the sacrum. Side-bending radiographs revealed the curve was very rigid. The flexibility was 9%. Postoperative standing radiographs show a correction of 61° and good balance (Figure 3A). The 45° thoracolumbar kyphosis was corrected to 0° (Figure 3B). The patient is extremely satisfied with the results. He has gained 10 cm in trunk height (Figure 3C).

A third case example is shown in Figure 4. This 36-year-old woman presented with polio-related neuromuscular scoliosis of 95°. Thoracolumbar kyphosis of 42° was noted. Severe trunk imbalance was noted. The spinal-pelvic obliquity (SPO) was 28°. Side-bending films showed the curve was very rigid with a flexibility of 14%. Postoperative standing radiographs showed a correction of 52% and a balance that was very much improved. The pelvis tilt was much corrected and the SPO was corrected to 10° (Figure 4A). The 42° thoracolumbar kyphosis was corrected to 5° (Figure 4B).

#### Discussion

Currently, scoliosis correction was usually carried out by rod derotation maneuver,<sup>1</sup> vertebra-to-rod method, or three-rod technique. The ultimate result of correction is a compromise between the rigidity of the scoliosis and the corrective forces provided by these methods. The corrective forces generated by these methods are limited by two factors. One is the reliability of bone-implant interfaces and the other is the stiffness of the metal rod. For example, with the rod derotation maneuver for treatment of large and rigid scoliosis using a rod contoured to the normal sagittal profile of the instrumented segments, the contoured metal rod might be flattened and deformed or the bone-implant interface might be broken during the derotation of the rod. Thus, the anterior release procedure is often indicated in large and rigid scoliosis to lessen the rigidity of the deformity and to improve the correctability of the spine.

The corrective forces generated by the cantilever bending technique are only limited by the reliability of bone-implant interfaces. The screws are immediately stable in all directions after insertion, and the superior biomechanical advantages of pedicle screws over other forms of spinal bone-implant interfaces allow cantilever bending technique to generate powerful corrective forces in all planes. The surgeon can decide how much corrective force to provide by observing how much correction

**Table 2. Modified SRS Outcomes Instrument Score**

Domain	Means	Score
Pain	4.22 (±0.73)	84.4%
Self-image/appearance	4.10 (±0.50)	82%
Function/activity	4.07 (±0.53)	81.4%
Mental health	3.97 (±0.65)	79.4%
Satisfaction with surgery	4.75 (±0.54)	95%

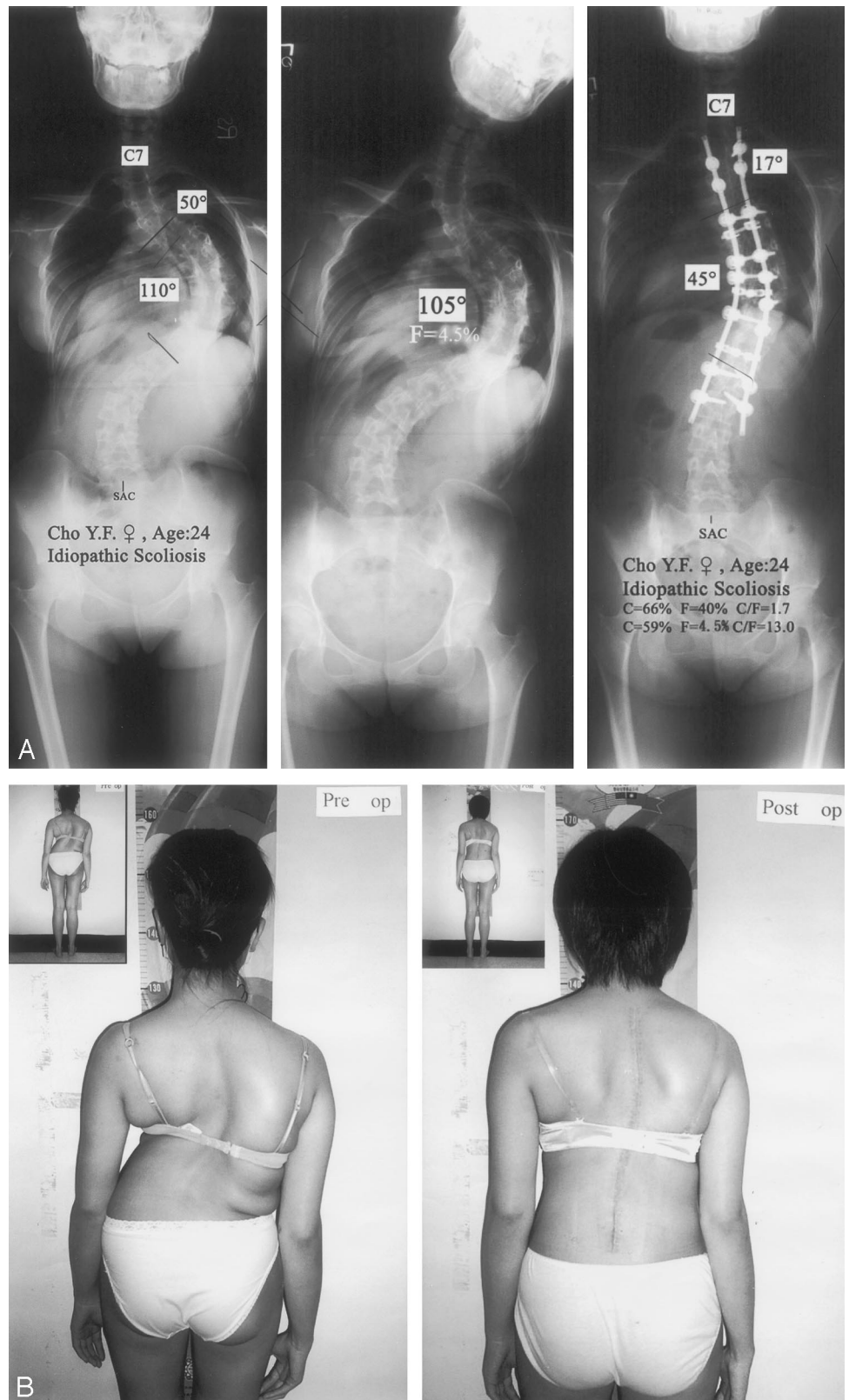


Figure 2. A 24-year-old female with a 110° King V idiopathic scoliosis. Radiographic views show (A) preoperative AP side-bending and postoperative AP. B, Preoperative and ultimate postoperative clinical appearance.

is achieved and estimating the reliability of bone-implant interface at both ends of instrumented segments during the operation. The corrective forces should not be increased if satisfactory correction has been obtained or there is a risk of damage to bone-implant interfaces. The superior biomechanical characteristics of the cantilever

bending technique apply a powerful lever corrective force to the spine to overcome the rigidity of the deformity and thereby avoid the need for anterior release procedures with its associated risk of complications.

The potential pitfalls and perioperative complications associated with anterior release procedures are numer-

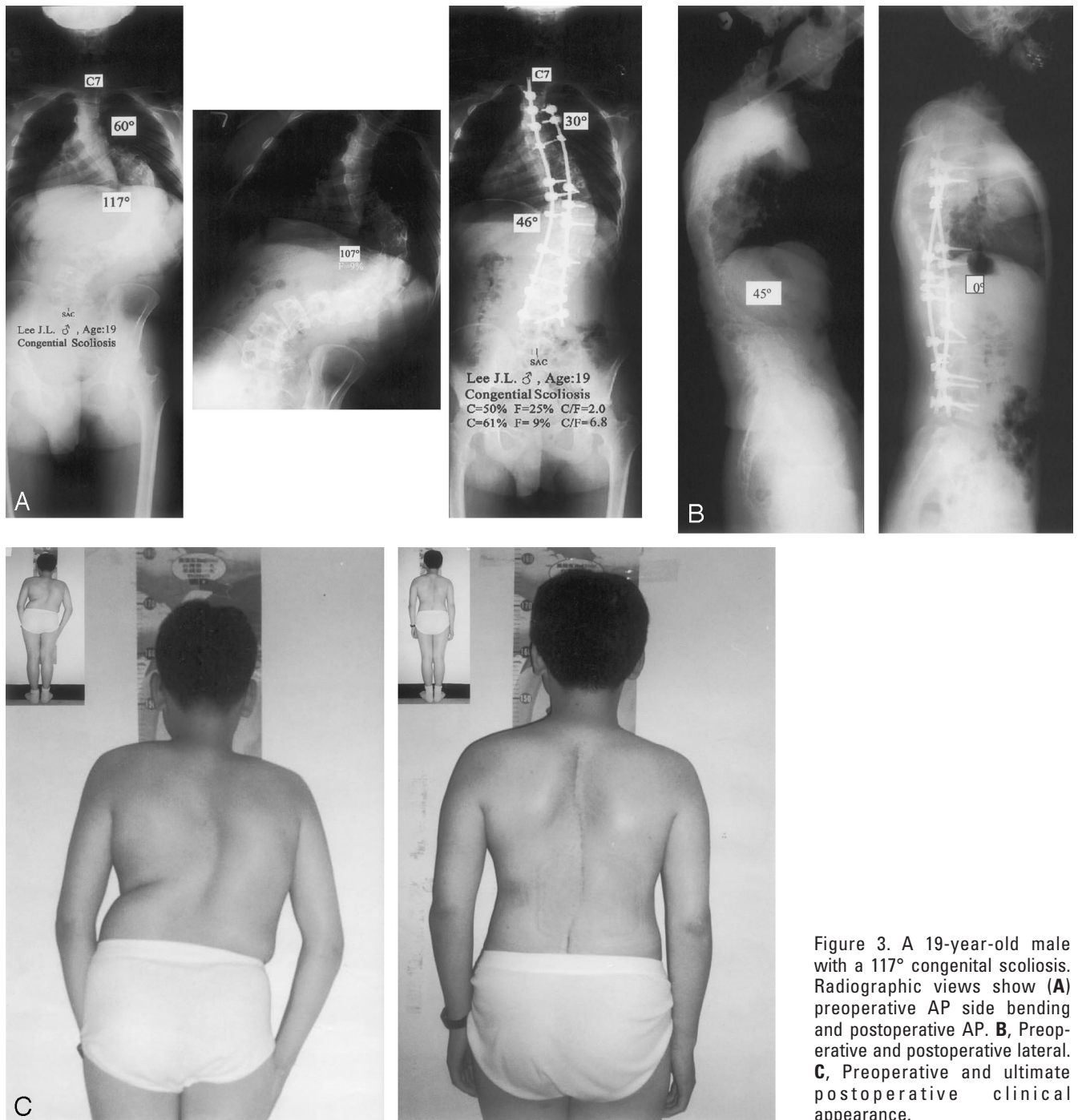


Figure 3. A 19-year-old male with a 117° congenital scoliosis. Radiographic views show (A) preoperative AP side bending and postoperative AP. B, Preoperative and postoperative lateral. C, Preoperative and ultimate postoperative clinical appearance.

ous. These include but are not limited to pulmonary dysfunction secondary to pneumothorax, atelectasis, effusion pneumonia, damage to great vessels, brachial plexus neuropraxia, postsympathectomy neuralgia, postthoracotomy syndrome, and visceral injury.<sup>4-8</sup> Also, the approach to the spine *via* anterior thoracotomy directly involves dissection through the latissimus dorsi, serratus anterior, and intercostals musculature that may complicate postoperative rehabilitation and ipsilateral upper extremity function.<sup>9</sup> In all except one patient of this series, anterior release was not required. Without anterior release, the cantilever bending technique is a less invasive and safer procedure.

Surgeons began using pedicle screws for thoracic scoliosis in 1988. The vertical diameters of the pedicle increase steadily from T1 (7 mm) to L5 (15 mm). The horizontal diameters decrease from the 7 mm of T1 to the 5 mm of T5 and then gradually increase to the 16 mm of L5. Distance between the medial wall of the pedicle and the cord is 2-3 mm.<sup>10,11</sup> Pedicle screws are not widely used in the thoracic region because of the narrow width of the thoracic pedicles and the potential for neurologic complications. After treatment of a total of 462 patients with spinal deformity and 4604 thoracic pedicle screw insertions, Suk *et al*<sup>12</sup> concluded that thoracic pedicle screw fixation is a reliable method of treating

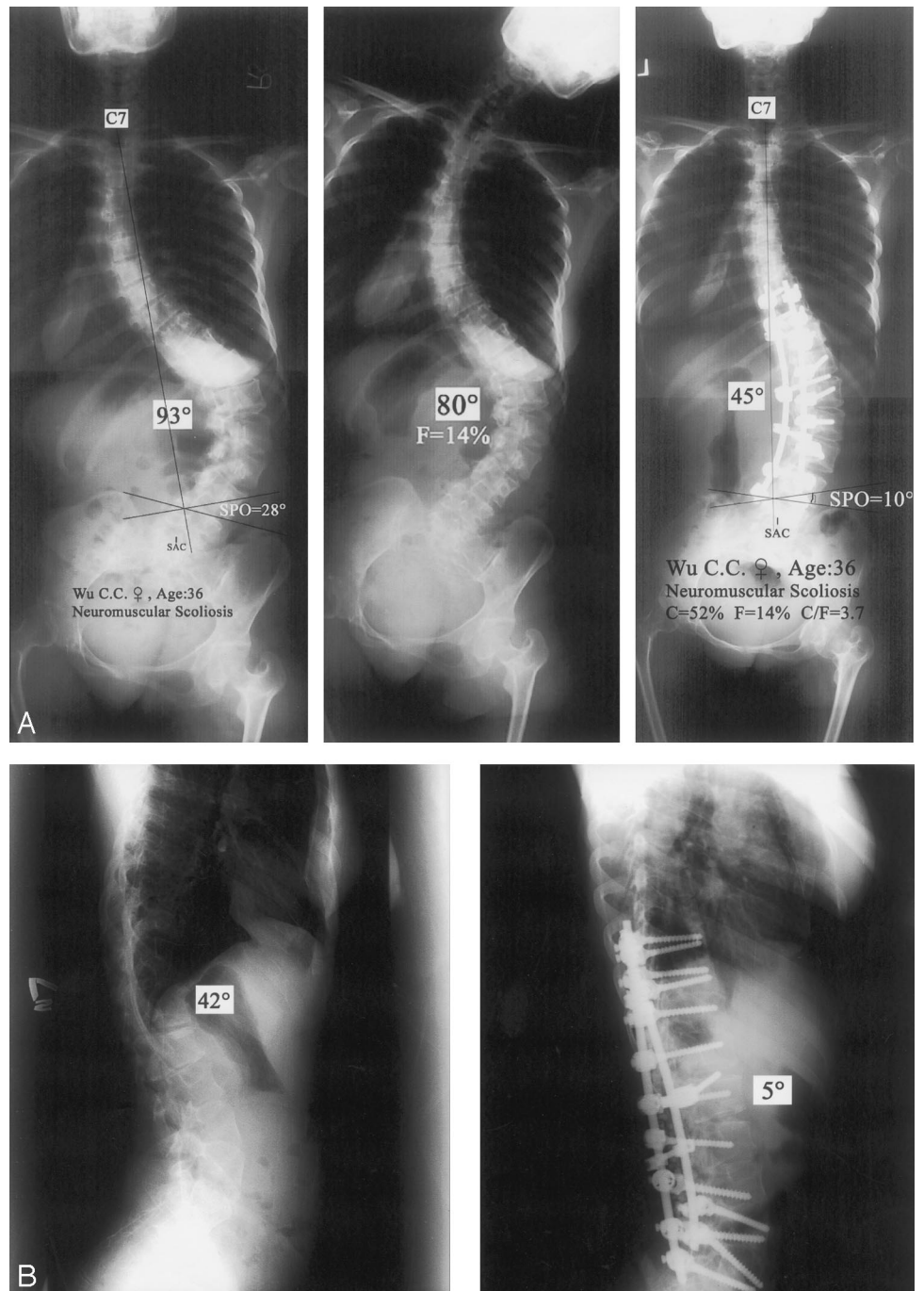


Figure 4. A 36-year-old woman with a 93° neuromuscular scoliosis. Radiographic views show (A) preoperative AP side bending and postoperative AP. B, Preoperative and postoperative lateral.

spinal deformity and has a high margin of safety. The author used 5 mm screws in the upper and lower thoracic region with no problem. Although technically demanding, the author had no great difficulty in accurately positioning the screws in the pedicles, and so far, has seen no neurologic complications.

Cantilever techniques have been widely used by surgeons to treat patients with scoliosis and kyphosis, through the use of *in situ* benders to lock the implant-deformity structure to the desired shape and expect the structure to stay in the shape after the *in situ* benders are removed. However, in most cases the structure would return to its original shape rather quickly after the release

of *in situ* bender; this is due to the elasticity of the structure as well as the spine itself, and this phenomenon has become more noticeable as the rigidity of the curvature increases. The direct outcome of this situation is that the correction is less successful than one would hope for. In other words, the effectiveness of this treatment has become less desirable due to the way we use *in situ* benders today.

In this report, the author used *in situ* benders to bend the convex rod to correct rigid scoliosis and used the concave rod to support and maintain the achieved correction. The *in situ* benders were not removed until the concave rod was also secured to the pedicle screws and

the transverse links were established, and the corrected curvature was rigidly fixed, so the achieved correction by the cantilever technique could be preserved. In addition, the author used pedicle screws instead of hooks as strong anchorages to maximize the effect of the cantilever technique.

The author does not intend to introduce a new technique, but rather a new method to implement the same technique through the use of *in situ* benders alone to treat the rigid and large scoliosis in a single posterior procedure and obtain the optimal result.

Most surgeons would recommend traction films to assess the true flexibility. A limitation of this study was the use of side-bending radiographs (made with voluntary effort while lying supine) to record the flexibility of the curves. However, this is the method used at the author's institution to assess flexibility of the thoracic and lumbar spine before surgery. Before 1998, flexibility was one of the major indicators for anterior release. After the use of the cantilever bending technique was instituted for the management of scoliotic spines with large and rigid deformity, flexibility was no longer a criterion. After 1998, the author used a posterior approach and tried the cantilever bending technique first to correct all large and rigid scoliosis without any release procedure. If satisfactory correction could not be obtained, extensive posterior release and partial facetectomy were then performed for gaining more flexibility. The cantilever bending was followed to see whether or not satisfactory correction could be achieved. If not, anterior release procedures in one stage were performed. In this study, only 1 of the 41 patients needed subsequent posterior and anterior release procedures. On several occasions, side-bending radiographs revealed no significant change in the curve (flexibility 0°). Still, satisfactory correction could be obtained by this method alone.

In conclusion, the cantilever bending technique is an effective procedure for the management of scoliotic spines with large and rigid deformities. The superior biomechanical advantages of pedicle screws over other forms of spinal bone-implant interfaces used as strong anchorages allow enough corrective force to be applied to overcome the rigidity of the deformity by cantilever bending technique alone, thereby avoiding the need for anterior release as well as its complications and pitfalls.

The clinical value of the cantilever bending technique is demonstrated in this study by the reduced need for anterior release, fewer complications, and the high rates of patient satisfaction.

### ■ Key Points

- A combined anterior and posterior approach is currently used for treating the large and rigid scoliosis.
- Cantilever bending technique alone (without the use of anterior release) is an effective technique for correction of the large and rigid deformities of scoliotic spines of any etiology.
- The method results in good deformity correction and has a high margin of safety.
- Patient satisfaction is high.

### References

1. Cotrel Y, Dubousset J, Guillaumat M. New universal instrumentation in spine surgery. *Clin Orthop* 1988;227:10–23.
2. Asher MA, Lai SM, Burton DC. Further development and validation of the Scoliosis Research Society (SRS) Outcomes Instrument. *Spine* 2000;25:2381–6.
3. Haher TR, Gorup JM, Shin TM, et al. Results of the Scoliosis Research Society instrument for evaluation of surgical outcome in adolescent idiopathic scoliosis: a multicenter study of 244 patients. *Spine* 1999;24:435–40.
4. Fasciszewski T, Winter RB, Lonstein JE, et al. The surgical and medical perioperative complications of anterior spinal fusion surgery in the thoracic and lumbar spine in adults: a review of 1223 procedures. *Spine* 1995;14:1592–9.
5. Hodge WA, DeWald RL. Splenic injury complicating the anterior thoraco-abdominal surgical approach for scoliosis. *J Bone Joint Surg Am* 1983;65:396–7.
6. McAfee PC. Complications of anterior approaches to the thoracolumbar spine: emphasis on Kaneda instrumentation. *Clin Orthop* 1994;306:110–19.
7. Nakai S, Zielke K. Chylothorax. A rare complication after anterior and posterior spinal correction: report on six cases. *Spine* 1986;11:830–3.
8. Weis JC, Betz RR, Clements DH III, et al. Prevalence of perioperative complications after anterior spinal fusion for patients with idiopathic scoliosis. *J Spinal Disord* 1997;10:371–5.
9. Burd TA, Pawelek L, Lenke LG. Upper extremity functional assessment after anterior spinal fusion via thoracotomy for adolescent idiopathic scoliosis. *Spine* 2002;27:65–71.
10. Roy-Camille R, Saillant G, Mazel C. Plating of thoracic, thoracolumbar and lumbar injuries with pedicle screw plates. *Clin Orthop* 1986;17:147–59.
11. Zindrick MR, Wiltse LL, Doornik A, et al. Analysis of the morphometric characteristics of the thoracic and lumbar pedicles. *Spine* 1987;12:160–6.
12. Suk SI, Kim WJ, Lee SM, et al. Thoracic pedicle screw fixation in spinal deformities. *Spine* 2001;18:2049–57.