

# Apical Lordosating Osteotomy and Minimal Segment Fixation for the Treatment of Thoracic or Thoracolumbar Osteoporotic Kyphosis

Kao-Wha Chang, MD, Ying-Yu Chen, MD, Chien-Chung Lin, MD, Hsiang-Lan Hsu, BA, and Ke-Chun Pai, BA

## Study Design. Retrospective review.

**Objective.** To assess the effectiveness of apical lordosating osteotomy (ALO) and minimal segment fixation through a posterior approach for correcting thoracic or thoracolumbar osteoporotic kyphosis (OK).

**Summary of Background Data.** Current surgical options for OK involve a risk of complex surgery in elderly patients, graft problems (*e.g.*, graft dislodgement, subsidence, pseudarthrosis), and instrumentation problems (*e.g.*, adjacent-segment failure, implant pullout). A posterior-only approach was used to make the surgery less invasive and safer.

**Methods.** A total of 26 consecutive patients (average age 71.5 years, range 65–81) with thoracic or thoracolumbar OK underwent ALO. Mean follow-up was 3.2 years (range 2.1–6.1). Radiographic studies, complications, and patient satisfaction were assessed.

**Results.** Mean operating time was 137 minutes, and mean blood loss was 717 mL. In 8 patients with thoracic hyperkyphosis, mean Cobb angle was corrected from 82.7° (range 75°–97°) to 25.8° (range 18°–30°), indicating normal kyphosis. In 18 patients, thoracolumbar kyphosis of 56.3° (range 47°–71°) was corrected to –1.8° (range –11° to 7°). Sagittal imbalance was 12.1 cm before surgery and 4.9 cm afterward. Satisfactory correction was achieved in all patients, without anterior release. Local kyphosis was corrected to –9.1° from 53.6°, and mean vertebral kyphosis to –26.6° from 17.7°. In 17 patients with neurologic deficit, Frankel grades improved after surgery. No major complication occurred. All patients had improved pain, self-image, and overall satisfaction.

**Conclusions.** ALO and minimal segments fixation appear to hold promise for the treatment of thoracic or thoracolumbar OK, and may be safer with fewer complications. A larger series with more patients and surgeons is needed for confirmation.

**Key words:** graft problems, instrumentation problems, minimal segment fixation, osteoporotic kyphosis, apical lordosating osteotomy. **Spine 2005;30:1674–1681**

Most patients with osteoporotic kyphosis (OK) as a result of vertebral compression fracture (VCF) are treated palliatively with bed rest, analgesics, and orthotics. However, these measures do not restore spinal alignment. Bed rest accelerates bone loss<sup>1,2</sup> and leads to muscle deconditioning, which increases deformity. VCF that causes neurologic deficit is extremely rare.<sup>3,4</sup> However, these fractures can be associated with progressive collapse of the vertebral body and late kyphosis. In such cases, neurologic deficit occurs insidiously and worsens gradually. Neural compression caused by displaced bone fragments and late kyphosis can also produce neurologic deficit.<sup>5,6</sup> Because of the risks in elderly and patients with osteoporosis, surgery is limited to those with gross deformity that severely threaten the patient's well-being or neurologic status. The specific procedure remains controversial, and current options have 3 problems, including risk and complexity in elderly patients, graft problems, and instrumentation problems.

One option achieves sagittal correction *via* a posterior-only approach without an anterior procedure. Because only minimal segment fixation is required, it is less invasive and safer than other alternatives. Deformity correction is accomplished by performing transvertebral osteotomy for 3-column release, and by reconstructing the hardness and height of the middle column with cages so it can act as a hinge for closing-opening wedge correction at the apical vertebra. After correction, the apical vertebra is converted from a wedge to a lordotic wedge, hence the name apical lordosating osteotomy (ALO). We determined the effectiveness and clinical value of this technique for thoracic or thoracolumbar OK.

## Materials and Methods

**Patients.** A total of 31 patients undergoing ALO and minimal segment fixation between 1997 and 2001 were retrospectively evaluated. Patients underwent thoracic or thoracolumbar OK with neurologic compromise or severely compromised well-being. There were 26 patients who had follow-up for at least 2 years, 2 died within 2 years, and 3 dropped out. All patients had compression fractures. Mean duration from injury to surgery was 2.1 years, and average age at surgery was 71.5 years. The male-female ratio was 7:19, and average follow-up was 3.2 years. Causes of osteoporosis were primary and worse than Saville grade II.<sup>7</sup>

The patient's clinical records were reviewed for demographic data, operating time, intraoperative blood loss, neurologic improvement, and complications. Seventeen patients with neurologic deficit were graded using the Frankle classification

From the Taiwan Spine Center and Department of Orthopaedic Surgery, Armed Forces Taichung General Hospital, Taiwan, Republic of China.

Acknowledgment date: January 19, 2004. First revision date: May 11, 2004. Second revision date: July 14, 2004. Acceptance date: August 30, 2004.

The manuscript submitted does not contain information about medical device(s)/drug(s).

No funds were received in support of this work. No benefits in any form have been or will be received from a commercial party related directly or indirectly to the subject of this manuscript.

Address correspondence and reprint requests to Kao-Wha Chang, MD, Taiwan Spine Center and Department of Orthopaedic Surgery, Armed Forces Taichung General Hospital, Taiwan. No.348, Sec.2, Chung-Shan Road, Taiping City, Taichung Hsein, Taiwan, Republic of China; E-mail: iscspine@ms45.url.com.tw

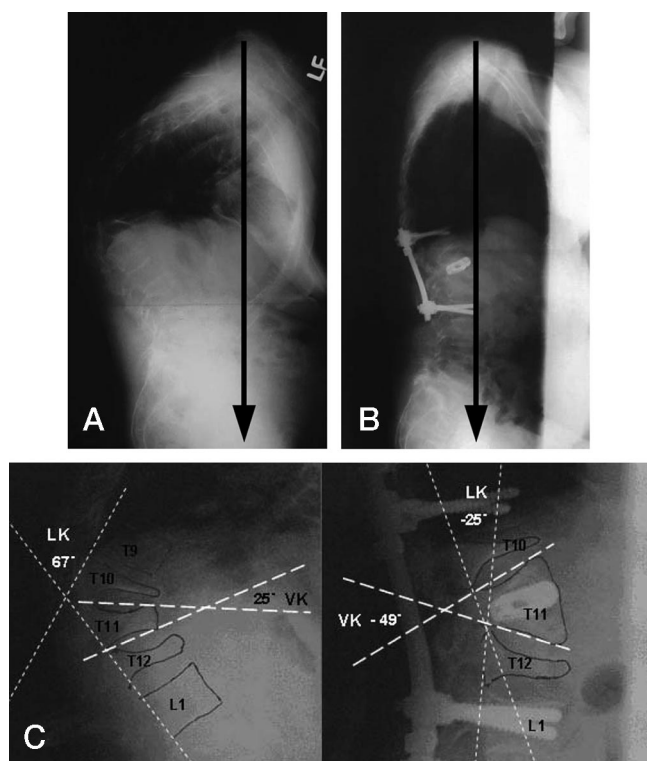


Figure 1. **A**, This 71-year-old woman presented with a severe thoracolumbar kyphosis and markedly positive sagittal balance as a result of wedge fractures at T10, T11, and T12. **B**, Standing radiographs obtained at 2 years postoperatively showed ALO at T11 to restore a normal sagittal alignment. **C**, The local kyphosis (LK) was corrected from 67° to -25°. The vertebral kyphosis (VK) was corrected from 25° to -49°.

system. Three patients had deficits of grade B, 7 had grade C, and 7 had grade D.

**Evaluations.** Radiography included preoperative and postoperative analyses for vertebral kyphosis, local kyphosis, sagittal alignment and balance, and postoperative arthrodesis and complications. Sagittal measurements were made on a 36-inch standing lateral view of the entire spine obtained with the patient's hips and knees fully extended. Sagittal offset was measured as the horizontal distance between the C7 sagittal plumb line and the posterior sacral prominence.<sup>8</sup> Because the postero-superior aspect of the S1 body was the reference, the normal neutral range for the sagittal alignment was considered to be 0–4 cm from this point (plumb line through the L5–S1 disc). Cobb measurements for thoracic kyphosis (T3–T12), the thoracolumbar junction (T10–L2), and the lumbar lordosis (L1–L5) were recorded. If the apex of deformity was between T3 and T10, the condition was defined as thoracic hyperkyphosis; between T11 and L1, it was thoracolumbar kyphosis; and between L2 and L5, lumbar kyphosis. Patients with lumbar kyphosis were excluded.

Local kyphosis in the apical region was estimated as the angle between lines from the posterior aspect of the 2 normal cranial vertebral bodies and from the posterior aspect of the 2 normal caudal vertebral bodies (Figures 1, 2). Vertebral kyphosis was measured from the superior endplate to the inferior endplate of the treated vertebral body. Magnetic resonance imaging was used to confirm the fracture and identify cord compression (retropulsed bone or disc). Seventeen patients had

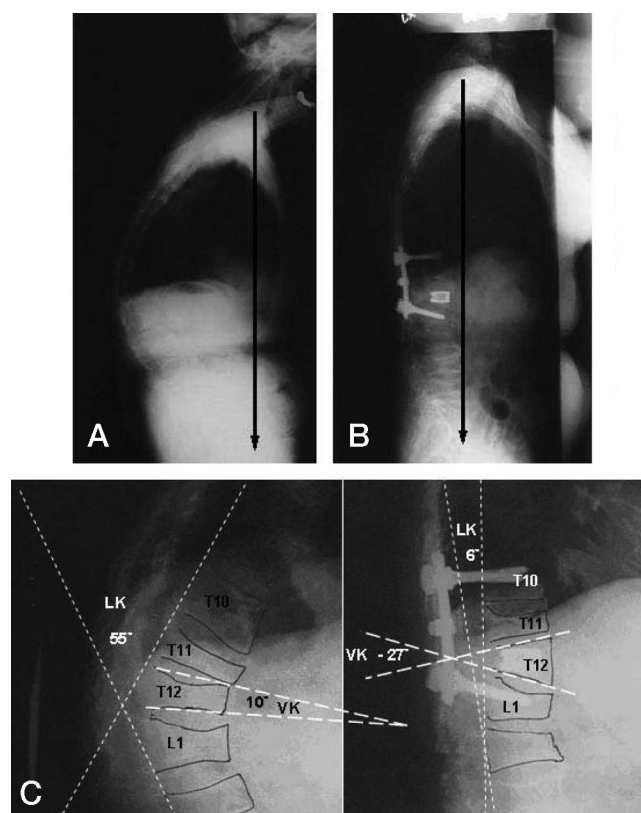


Figure 2. **A**, This 73-year-old man presented with a progressive and painful junctional thoracolumbar kyphosis as a result of wedge fractures at T11, T12, and L1. **B**, Standing radiographs obtained at 2 years postoperatively showed a normal thoracolumbar junction and good balance. **C**, The local kyphosis (LK) was corrected from 55° to 6°. The vertebral kyphosis (VK) was corrected from 10° to -27°.

neurologic compromise. A modified, self-administered Scoliosis Research Society instrument<sup>9,10</sup> was used to determine patient satisfaction with the treatment.

**Surgical Techniques.** The patient was positioned prone, with padding at the iliac crests, knees, shoulders, and chest, and with the abdomen free to reduce intraoperative bleeding. The apex of the deformity was over the hinge in the operating table so that as the osteotomy was closed, the table could be moved from the flexed position to more neutral alignment. A standard posterior midline incision was made 1 or 2 segments above and below the apex. The spine was exposed to the tip of the transverse processes bilaterally, with a strictly subperiosteal approach to reduce bleeding. Pedicle screws were inserted at the normal level immediately above and below the osteotomy level. The pedicles of the apical vertebrae were decorticated with a rongeur to facilitate guide-pin insertion. The pedicle was entered with a small-diameter curette guided by intraoperative fluoroscopy and radiography. The ideal path was from the lateral side of the medial wall of the pedicle to the anteromedial wall of the vertebral body, in the middle between both endplates. The path was gradually enlarged with a larger-diameter curette until the smallest cage trial could be inserted. The lamina and pedicles of the apical vertebra were removed (Figure 3A).

A blunt-end cage trial was hammered to penetrate the anterior cortex of the apical vertebral body transvertebrally and

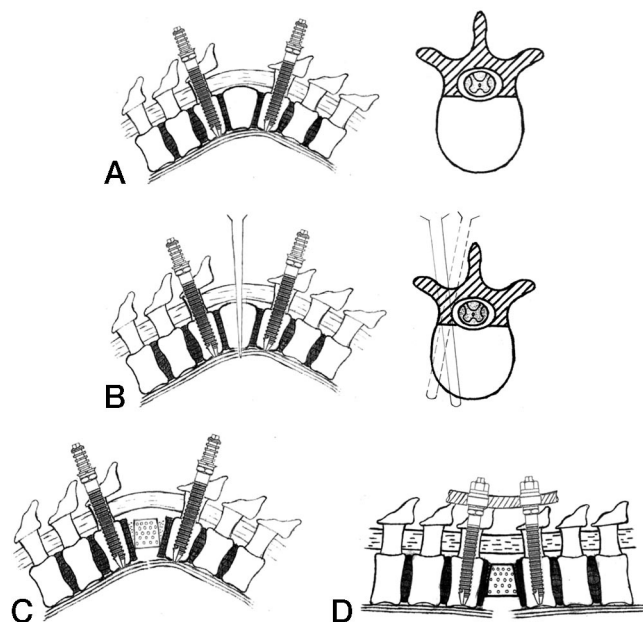


Figure 3. A–D, Surgical technique of ALO.

bilaterally to fracture the cortex (Figure 3B). The path in the middle column was enlarged by pushing the cancellous bone up and down until a cage trial could be squeezed between the upper and lower vertebral endplates. The posterior cortex of the body of the apical vertebra was carefully removed using a curette or rongeur bilaterally. The posterior and middle columns were completely released. Mathy® contact fusion cages (Mathy® Medical Ltd., Switzerland) of equal size were chosen; their cavities were filled with cancellous bone from the laminectomy. The cages were impacted into the vertebral body until their posterior edge was just buried in the middle column to maintain its height. The middle column was the hardest of the 3 columns and could act as a hinge during the following pivotal corrective procedures without fear of collapse or shortening.

The operating table was slowly returned to its neutral position. The surgeon simultaneously pushed at the kyphotic apex until satisfactory correction was achieved (Figure 3C). The sound of a fracture of the anterior cortex and anterior longitudinal ligament was sometimes heard. We closed down the lateral mass tightly at the end of the corrective procedures. The correction was fixed with precontoured rods and fused with autogenous bone grafts (Figure 3D). The roots and dura were checked to ensure that they were clear of residual compression by enlarging the canal centrally. A Woodson elevator was passed up and down the canal through the area of central decompression to detect dorsal neural compression created by closure of the osteotomy. We performed wake-up tests after osteotomy closure. Patients were allowed to ambulate 48 hours

Table 2. Modified Scoliosis Research Society Outcomes Instrument Score

Domain	Mean ( $\pm$ SD)	Score (%)
Pain	3.93 ( $\pm$ 0.61)	78.6
Self-image/appearance	4.11 ( $\pm$ 0.3)	82.2
Function/activity	3.94 ( $\pm$ 0.44)	78.8
Mental health	3.93 ( $\pm$ 0.65)	78.6
Satisfaction with surgery	4.67 ( $\pm$ 0.53)	93.4

after surgery. They used a custom-made thoracolumbar orthosis for 3–6 months.

## Results

All patients with neurologic deficit had postoperative improvement. Of the 3 patients with an original Frankle grade B, 2 improved to grade C, and 1 improved to grade D. Of the 7 patients with grade C, 4 improved to grade D, and 3 improved to grade E. All 7 patients with Frankle grade D before surgery recovered normal strength and sensation after surgery. Thoracic hyperkyphosis was substantially improved in 8 patients, and thoracolumbar kyphosis was effectively corrected in 18 (Table 1). Corrections in sagittal imbalance, local kyphosis, and vertebral kyphosis are shown in Table 1. No patient had a notable loss of correction between discharge and final follow-up.

Mean estimated blood loss was 717 mL (range 310–963). Mean operating time was 137 minutes (range 105–186). No perioperative deaths or neurovascular complications occurred. Postoperative pneumonia developed in one patient, which was successfully treated with respiratory therapy and antibiotics. One superficial infection was treated with incision and drainage, and resolved uneventfully. No screw pullout, adjacent-segment fracture, pseudoarthroses, or graft dislodgment or subsidence was observed.

A total of 19 patients were extremely satisfied with treatment, 7 were somewhat satisfied, and none were dissatisfied. There were 16 patients who would definitely repeat their surgery if needed, and 10 probably would. Postoperative satisfaction scores averaged 93% (Table 2).

## Discussion

Osteoporosis results in progressive bone mineral loss and changes the bony architecture, leaving the spinal column vulnerable to compression fractures, often with no or minimal trauma. Osteoporotic compression fractures

Table 1. Sagittal Alignment Correction in 32 Patients

Deformity	No. of Patients	Preop. (range)	Postop. (range)	Correction
Thoracic hyperkyphosis	8	82.7° $\pm$ 21.43° (75°–97°)	25.8° $\pm$ 10.68° (18°–30°)	56.9°
Thoracolumbar kyphosis	18	56.3° $\pm$ 20.47° (47°–71°)	–1.8° $\pm$ 3.39° (–11° to 7°)	58.1°
Sagittal imbalance	26	12.1 $\pm$ 4.23 cm (8.9–12.3)	4.9 $\pm$ 3.11 cm (3.4–5.5)	7.2 cm
Local kyphosis	26	53.6° $\pm$ 19.83° (36°–71°)	–19.1° $\pm$ 3.9° (–25° to 8°)	62.7°
Vertebral kyphosis	26	17.7° $\pm$ 5.54° (8°–27°)	–26.6° $\pm$ 6.99° (–12° to –53°)	44.3°

have been described as stable spinal injuries, and in most cases, they are well managed with nonoperative treatment, including bed rest, analgesia, and bracing for symptom control. However, these treatments do nothing to restore spinal alignment and progressive collapse of vertebral body, which can lead to kyphosis.

Kyphotic deformity in the osteoporotic spine can create a biomechanical environment promoting additional fractures. The kyphotic deformity anteriorly shifts the patient's center of gravity, resulting in more flexion bending moments around the apex of the kyphosis, which in turn promote further increases in kyphotic angulation and additional fractures.<sup>11,12</sup> Clinical studies have shown that the risk of a new vertebral fracture during the first year after an incident, VCF increases 5–25 times above baseline,<sup>13–15</sup> with the vertebra adjacent to the previously fractured level at particular risk.<sup>16,17</sup> Each vertebral fracture results in a 9% loss of predicted forced vital capacity,<sup>18</sup> suggesting that the restrictive changes in thoracic anatomy are particularly harmful to patients with preexisting lung disease. Whether the fracture is painful or not, the spinal deformity caused by 2 or more fractures dramatically affects the patient's health, activities of daily living, and medical costs as a consequence of lost lung capacity, lost appetite, reduced mobility, chronic pain, and/or clinical depression.<sup>19–21</sup> These effects are related to the severity of deformity<sup>17–19</sup> and are partly independent of pain.<sup>22,23</sup>

Regarding the neurologic aspects, compression fractures in elderly patients with osteoporosis have been considered a benign entity. Progressive kyphosis and neurologic deficit after an osteoporotic vertebral body fracture account for only a small number of cases.<sup>3,4</sup> However, progressive vertebral body collapse may result in significant kyphosis and insidious-onset neurologic deficit.

Surgical treatment is usually required for OK with severe physical disability and neurologic compromise secondary to VCF because nonoperative treatment is generally ineffective. Surgery aims to improve neurologic deficits with neural decompression, restoration of normal alignment by correcting the deformity, and stabilization of the spinal column by arthrodesis.<sup>24</sup> However, the specific procedure for thoracic or thoracolumbar OK remains controversial. Posterior spinal fusion alone is not considered sufficient. Kostuik<sup>25</sup> and Kaneda<sup>26</sup> *et al* reported success with anterior decompression and stabilization, and anterior instrumentation for posttraumatic kyphosis. Other investigators insist that anterior decompression and fusion should not be used alone to correct rigid kyphosis, recommending additional posterior instrumentation and fusion to promote arthrodesis.<sup>27–29</sup> They believe the anterior approach is better because it is well tolerated, it addresses the deformity directly, it allows restoration of the anterior and middle column, and unlike a posterior procedure, it does not require manipulation of the neurologic structures.

Another procedure is posterior osteotomy. A posterior-only approach has several advantages in correcting

sagittal deformity: It is a single-stage surgery, it addresses the deformity at the apex, it creates compressive forces at the osteotomy site, and minimal osteotomies can offer maximal correction.

Deformity correction is a goal only if it does not pose an inordinate risk. An anterior or combined anteroposterior approach, which is well tolerated in most patients, presents risks to the chest or abdomen, possibly inducing serious hazards in elderly patients. Potential perioperative complications of anterior release procedures include, but are not limited to, pulmonary dysfunction secondary to pneumothorax, atelectasis, effusion pneumonia, damage to the great vessels, brachial plexus neuropraxia, post-sympathectomy neuralgia, postthoracotomy syndrome, and visceral injury.<sup>30–34</sup> The approach to the spine *via* anterior thoracotomy directly involves dissection through the latissimus dorsi, serratus anterior, and intercostal musculature, which may complicate postoperative rehabilitation and ipsilateral upper-extremity function.<sup>35</sup> In addition, success with anterior structural bone grafts is limited by poor bone quality, and graft problems are always a consideration.

Suk *et al*<sup>36</sup> compared the surgical results of combined anteroposterior procedures and posterior closing wedge osteotomy procedures in patients with posttraumatic kyphosis, and neurologic compromise secondary to osteoporotic fractures. They concluded that although the posterior closing wedge osteotomy procedure is technically demanding and requires strict attention to detail to avoid neurologic complications, it offers better kyphosis correction with significantly less operating time, blood loss, and postoperative morbidity. In our study, anterior release was not required. We believe that without anterior release, kyphosis correction surgery is less invasive and safer for elderly patients.

Posterior surgical options to correct kyphosis can be categorized by the fulcrum across which the correction is achieved. One option is closing-opening wedge osteotomy with hinging in the middle column, and another is closing wedge osteotomy with hinging in the anterior column. Smith-Peterson *et al*<sup>37</sup> originally described closing-opening wedge osteotomy to correct cases of kyphosis that mainly occurred in relation to ankylosing spondylitis. The procedure was a limited osteotomy involving only the posterior element. Given the spinal fragility with ankylosing spondylitis, transvertebral osteotomy is not necessary to produce release of the anterior structures. The anterior and middle columns are opened by manual osteoclasis rather than transvertebral osteotomy. Thus, the height and hardness of the middle column are not destroyed, and they can act as a hinge during correction without causing a large length discrepancy between the vertebral column and neural structure. Neural tissue redundancy is not a problem that causes neurologic complications during the corrective procedures. Therefore, this technique can be used in the lumbar cauda equina segment, and in the thoracic and thoracolumbar cord segments.

Thomasen<sup>38</sup> modified the procedure with closing wedge osteotomy. This transvertebral osteotomy involves 3 columns of the treated vertebra and achieves sagittal-plane correction by placing the hinge of correction anteriorly, shortening the spine and avoiding an anterior opening in the anterior and middle columns. This procedure has been widely used to correct deformity caused by ankylosing spondylitis and posttraumatic kyphosis. Posterior spinal shortening was first performed for an osteoporotic compression fracture in a 74-year-old woman with T12 vertebral collapse.<sup>39</sup> After the surgeons performed initial resection of the lamina and caudal facet joints of the fractured vertebra, they inserted pedicle screws 2 vertebrae above and below this level. The pedicles were resected, followed by decancellation of the vertebra. Compression was applied until the 2 endplates came into contact, resulting in a short vertebral body and kyphotic correction.

Generally, correcting spinal deformity by shortening the spinal column has been considered safe since the publication of Leatherman and Dickson's report.<sup>40</sup> However, excessive shortening is dangerous, and a safety limit exists. Gertzbein and Harris<sup>24</sup> limited their corrections to approximately 30°–40°. If kyphotic correction is >40° with closing wedge osteotomy, the spinal cord may be too long for the shortened column. It may become curved or even kinked and potentially damaged because the hinge is positioned at the anterior longitudinal ligament at the apex of the deformity. In their report on posterior transvertebral osteotomy, Lehmer *et al*<sup>41</sup> recommend that correction at any one level should not exceed approximately 35°, otherwise dural buckling may occur. Describing transpedicular wedge resection osteotomy, Berven *et al*<sup>42</sup> recommend that correction of sagittal deformity should be below L1 and of a magnitude correctable with a closing wedge measuring <45°.

The sagittal deformity can be satisfactorily corrected with a posterior osteotomy only if the 3 vertebral columns and the anterior longitudinal ligament can be adequately released. Transvertebral osteotomy can provide adequate 3-column release for OK. However, for subsequent correction of OK in the thoracolumbar and thoracic spine, the hinge should be placed posteriorly in the middle column to minimize potential damage of neural tissue redundancy over the cord segment of the spine. The height and hardness of the middle column of the apical vertebrae, destroyed by transvertebral osteotomy, must be reconstructed to act as a hinge without collapse or shortening during the pivotal corrective procedures. We accomplished this process by implanting 2 sizable cages and compacting cancellous bone in the middle column. The procedures combined characteristics of the method by Smith-Peterson *et al*<sup>37</sup> and the transvertebral procedure for correcting sagittal deformity. It is a transvertebral procedure, but the fulcrum was placed in the middle column, opening the anterior column and closing the posterior osteotomy. An average correction of 57.5°

(range 44°–72°) was obtained without neurologic complication, showing the safety of this technique.

This method provides an optimal biomechanical environment. The cancellous bone in the middle column of the apical vertebra was compacted, and under compression to promote fusion and limit dislodgment. The apical vertebra was strengthened with cages and was, therefore, strong enough to withstand compression and load from early postoperative mobilization. The cages were intra-vertebral, under compression, and surrounded by bone; therefore, the likelihood of dislodgment was small. All of the cages seem to have fused with the vertebrae, and no radiolucent line or motion was found on follow-up radiographs. The cages rested on the firm endplate, namely, the disc mattress rather than a weak endplate. The trabecular mattress is the conventional anterior strut on which grafts are rested. Osteoporosis preferentially affects trabecular bone. The degenerative discs, along with their endplates, are the strongest portions of the spinal column in the osteoporotic spine, and these should be preserved as cornerstones for reconstructive procedures in OK. No patient had cage graft subsidence.

Reconstruction of anatomic alignment reduces instrumentation failure and increases fusion. Optimally, the entire length of the applicable segments should be under compression to promote arthrodesis, which requires a direct line of weight transfer from each end of the segment. In substantial residual kyphosis, the posterior elements are in tension, tending toward the formation of pseudarthrosis.<sup>12</sup> Generally, if the kyphosis cannot be corrected to <55°, anterior fusion should be added to achieve a graft in compression<sup>43</sup> and relieve posterior tensile forces. In our study, local sagittal alignment was improved by 62.7°, and the apical vertebrae were converted from kyphosis to lordosis, improving by 44.3°. The ultimate value is a positive effect on global spinal alignment and balance. Mean sagittal plumb line improved from 12.1 to 4.9 cm. Thoracic hyperkyphosis was corrected from 82.7° to 25.8°, and thoracolumbar kyphosis was corrected from 56.3° to –1.8°, indicating normal alignment.

Risks of implant failure are significant when instrumentation of the osteoporotic spine is performed. Techniques to reduce instrumentation pullout during or after surgery include the use of multiple points of segmental fixation, the use of sublaminar wires, under-tapping or not tapping the screw hole before pedicle screws are used, combining the use of pedicle screws with laminar hooks at the same level, accepting less correction of the deformity, and not ending the instrumentation within a kyphotic segment.<sup>44</sup> However, kyphosis correction uses cantilever bending forces (Figure 4). Forces on the superior and inferior ends of the instrumentation construct resist anterior displacement of the spine relative to the rods. Therefore, failure is manifested by rod fracture at the apex of the deformity or, more likely, failure of the segmental fixation at either end of the construct. The most effective way to prevent implant pullout when cor-

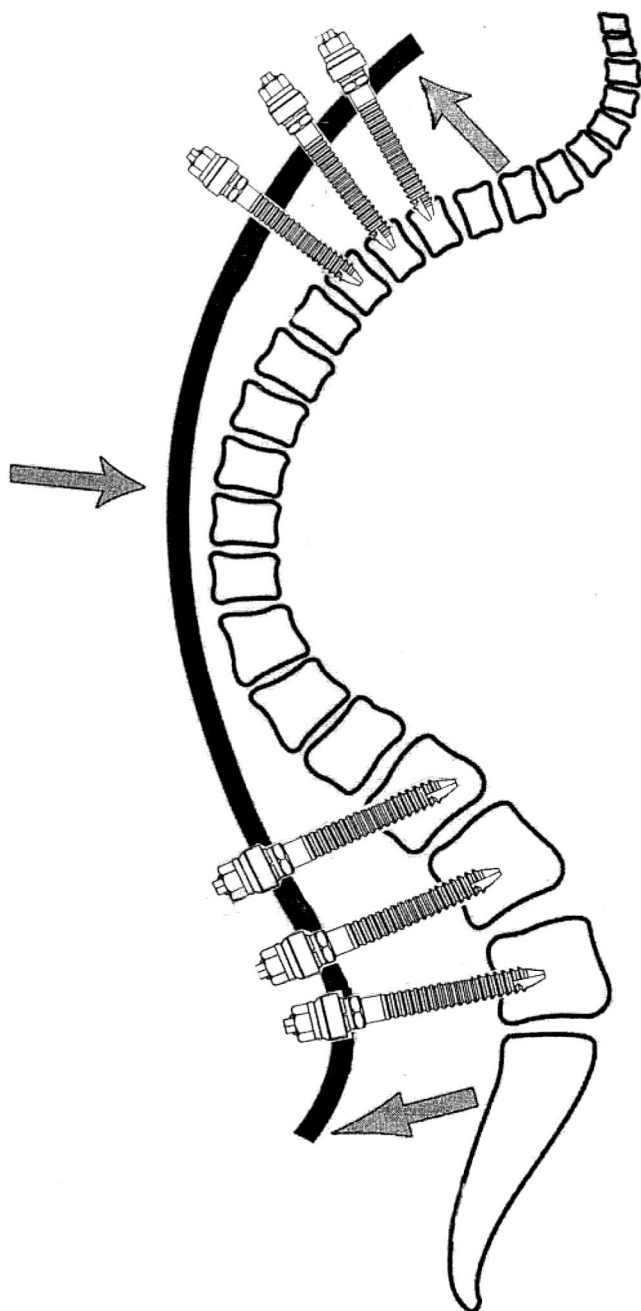


Figure 4. Cantilever forces applied during correction of the kyphotic spine. The posteriorly directed forces at the proximal and distal aspect of the instrumentation result in the highest potential for failure.

recting OK is to minimize the posteriorly directed force (Figure 4). The kyphosis must be adequately released. Correction is accomplished by using manual and posture correction, and finally is fixed by using implants. The implant can be used only as a fixator and not a corrector.

In this series, the posterior and middle columns of the apical vertebrae were thoroughly released under direct visualization. The anterior vertebral cortex and the anterior longitudinal ligament were mostly penetrated and weakened by using the blunt end of a cage trial. This structure can be easily fractured by firmly pushing on the

apex of the kyphosis during the pivotal corrective procedures. Deformity correction is accomplished by adjusting the position of the operating table and by manual correction. The implant fixes the final alignment. Reconstructing the anatomic alignment and changing the local spinal curvature from kyphosis to lordosis markedly lessens the posteriorly directed force and, thus, decreases the incidence of postoperative screw pullout as well.<sup>39</sup> No screw pullout occurred in this series.

Some advocate multiple points of fixation to decrease the stresses at any site and reduce the incidence of screw pullout. However, long instrumentation increases next-segment failure and may contribute to or increase susceptibility to junctional kyphosis. One can predict adjacent-segment failure by assuming an Archimedean viewpoint in which the segments fixed by rigid instrumentation are conceived as levers, pulling across both end segments as the fulcrum. This mechanism illustrates how next-segment failure increases with fusion-segment length. Etebar and Cahill<sup>45</sup> concluded that advanced age (older than 60 years), osteoporosis, and a long fusion segment are risk factors. Our average patient age was 71.5 years, and all patients were osteoporotic. We used minimal segment fixation with postoperative thoracolumbar bracing for 3–6 months and observed no adjacent-segment failure. Although adequate purchase of the implant in osteoporotic bone remains an issue,<sup>46–48</sup> application of the transpedicular systems enables fusion under favorable compression conditions.<sup>49</sup>

The risks of anesthesia and prolonged recumbency are relatively high, particularly in elderly patients. Posterior surgery can be performed safely in this high-risk population. No major medical complications occurred during our study, and all patients completed the surgeries. Blood loss and operating time were reasonable, given the magnitude of surgery. Shorter procedures generally result in less airway edema because of prolonged prone positioning, less blood loss, and less pulmonary edema from massive fluid shifts, reducing postoperative cardiopulmonary complications. In our series, no patient died or had such complications.

This study had 3 deficiencies. First, we did not document dynamic mobility of osteoporotic VCF<sup>50–52</sup> in the present patients. Mckiernan *et al*<sup>50</sup> compared preoperative standing lateral radiographs of VCF with supine cross-table lateral radiographs to determine the presence or absence of dynamic mobility. Dynamic fracture mobility was shown in 44% of patients who underwent vertebroplasty. Their report documented the previously unrecognized occurrence of dynamic fracture mobility in many osteoporotic VCFs. Faciszewski and Mckiernan<sup>52</sup> compared preoperative hyperextension radiographs with preoperative standing radiographs and found that the height of mobile fractures increased an average of 68% with dynamic positioning alone. Fracture mobility can be substantial and clinically important, and nearly 40% of symptomatic VCFs, which may account for considerable correction that can be obtained by positioning

the patient alone. Any intervention that seems to correct for the deformities must control for the occurrence of dynamic fracture mobility. We might have missed some degree of spontaneous correction of the deformity by not documenting the presence or lack of dynamic mobility of these fractures.

Second, we did not document the flexibility of these deformities. Flexibility is one of the major indicators for anterior release at our institution. In this study, anterior release was not required; therefore, flexibility of the kyphotic deformities was not documented. However, preoperative dynamic (hyperextension) radiography or at least supine radiography to assess the flexibility of these deformities is standard practice to anticipate the degree of postural fracture reduction and angular correction. The absence of this information does weaken our argument about the degree of correction obtained.

A third potential study limitation is the lack of a control group. Patients with primary osteoporosis who were undergoing osteotomies were not suitable as control subjects because the magnitude of their kyphosis was less, and the location of their kyphosis differed. Multicenter comparisons would have been difficult because of wide variations in surgical technique.

ALO and minimal segment fixation appear to hold promise for the treatment of thoracic or thoracolumbar OK, and they may prove safer with fewer complications. However, this was a small series with a limited clinical group. A larger series of patients, including multiple surgeons, is necessary to confirm this statement.

### ■ Key Points

- Current anterior and/or posterior operative procedures for thoracic or thoracolumbar OK have 3 major problems: (1) they are risky and complex in elderly patients; (2) they have a relatively high incidence of graft problems (e.g., graft dislodgement, subsidence, pseudarthrosis), and (3) they have a relatively high incidence of instrumentation problems (e.g., implant pullout, adjacent-segment failure).
- ALO with a posterior-only approach obviates anterior release procedures and their associated morbidity.
- This method provides an optimal biomechanical environment for fusion, and preventing graft and instrumentation problems. It also minimizes the risk of neural tissue redundancy over the spinal cord segment by positioning the fulcrum of correction in the middle column of the apical vertebra.
- This technique results in good correction of deformities, and has few complications and a large margin of safety.
- Patient satisfaction is high.

### References

1. Convertino VA, Bloomfield SA, Greenleaf JF. An overview of the issues: Physiological effects of bed rest and restricted physical activity. *Med Sci Sports Exerc* 1997;29:187-90.
2. Uthoff HK, Jaworski ZF. Bone loss in response to long term immobilization. *J Bone Joint Surg Br* 1978;60:420-9.
3. Heggenes MH. Spine fracture with neurological deficit in osteoporosis. *Osteoporos Int* 1993;3:215-21.
4. Salomon C, Chopin D, Benoist M. Spinal cord compression: An exceptional complication of spinal osteoporosis. *Spine* 1988;13:222-4.
5. Sutherland CJ, Miler F, Wang GJ. Early progressive kyphosis following compression fractures: Two cases reports from a series of "stable" thoracolumbar compression fractures. *Clin Orthop Relat Res* 1983;173:216-20.
6. Tanaka S, Kubota M, Fujimoto Y, et al. Conus medullaris syndrome secondary to an L1 burst fracture in osteoporosis. *Spine* 1993;18:2131-4.
7. Saville PD. A quantitative approach to simple radiographic diagnosis of osteoporosis: Its application to the osteoporosis of rheumatoid arthritis. *Arthritis Rheum* 1967;10:416-22.
8. Jackson RP, McManus AC. Radiographic analysis of sagittal plane alignment and balance in standing volunteers and patients with low back pain matched for age, sex, and size: A prospective controlled clinical study. *Spine* 1994;19:1611-8.
9. Asher MA, Lai SM, Burton DC. Further development and validation of the Scoliosis Research Society (SRS) Outcomes Instrument. *Spine* 2000;25:2381-6.
10. Haheer TR, Gorup JM, Shin TM, et al. Results of the Scoliosis Research Society instrument for evaluation of surgical outcome in adolescent idiopathic scoliosis: A multicenter study of 244 patients. *Spine* 1999;24:435-40.
11. Belmont PJ Jr, Polly DW Jr, Cunningham BW, et al. The effects of hook pattern and kyphotic angulation on mechanical strength and apical rod strain in a long-segment posterior construct using a synthetic model. *Spine* 2001;26:627-35.
12. White AA, Panjabi MM, Thomas CL. The clinical biomechanics of kyphotic deformities. *Clin Orthop Relat Res* 1977;8-17.
13. Nevitt MC, Ettinger B, Black DM, et al. The association of radiographically detected vertebral fractures with back pain and function: A prospective study. *Ann Intern Med* 1998;128:793-800.
14. Nevitt MC, Thompson DE, Black DM, et al. Effect of alendronate on limited activity days and bed-disability days caused by back pain in postmenopausal women with existing vertebral fractures. *Arch Intern Med* 2000;160:77-85.
15. Wasnich U. Vertebral fracture epidemiology. *Bone* 1996;18:1791-6.
16. Haczynski J, Jakimiuk A. Vertebral fractures: A hidden problem of osteoporosis. *Med Sci Monit* 2001;7:1108-17.
17. Ross PD, Davis JW, Epstein RS, et al. Pre-existing fractures and bone mass predict vertebral fracture incidence in women. *Ann Intern Med* 1991;114:919-23.
18. Leech JA, Dulberg C, Kellie S, et al. Relationship of lung function to severity of osteoporosis in women. *Am Rev Respir Dis* 1990;141:68-71.
19. Cook DJ, Guyatt GH, Adachi JD, et al. Quality of life issues in women with vertebral fracture due to osteoporosis. *Arthritis Rheum* 1993;36:750-6.
20. Lyles KW, Gold DT, Shipp KM, et al. Association of osteoporotic vertebral fractures with impaired functional status. *Am J Med* 1993;94:595-601.
21. Silverman SL. The clinical consequences of vertebral compression fracture. *Bone* 1992;13(suppl 2):27-31.
22. Kado DM, Browner WS, Palermo L, et al. Vertebral fractures and mortality in older women: A prospective study. *Arch Intern Med* 1999;159:1215-20.
23. Leidig-Bruckner G, Minne HW, Schlaich C, et al. Clinical grading of spinal osteoporosis: Quality of life components and spinal deformity in women with chronic low back pain and women with vertebral osteoporosis. *J Bone Miner Res* 1997;12:663-75.
24. Gertzbein SD, Harris MB. Wedge osteotomy for the correction of posttraumatic kyphosis. *Spine* 1992;17:374-9.
25. Kostuik JP, Matsusaki H. Anterior stabilization, instrumentation and decompression for post-traumatic kyphosis. *Spine* 1989;14:379-86.
26. Kaneda K, Asano S, Hashimoto T, et al. The treatment of osteoporotic posttraumatic vertebral collapse using the Kaneda device and a bioactive ceramic vertebral prosthesis. *Spine* 1992;17:295-303.
27. Malcolm BW, Bradford DS, Winter RB, et al. Post-traumatic kyphosis: A review of forth-eight surgically treated patients. *J Bone Joint Surg Am* 1981;63:891-9.
28. McAfee PC, Bohman HH, Yuan HA. Anterior decompression of traumatic thoracolumbar fractures with incomplete neurological deficit using a retroperitoneal approach. *J Bone Joint Surg Am* 1985;67:89-104.
29. Eysel P, Schwitalle M, Oberstein A, et al. Preoperative estimation of screw fixation strength in vertebral bodies. *Spine* 1998;15:174-80.
30. Fasciszewski T, Winter RB, Lonstein JE, et al. The surgical and medical

- perioperative complications of anterior spinal fusion surgery in the thoracic and lumbar spine in adults: A review of 1223 procedures. *Spine* 1995;14:1592-9.
31. Hodge WA, DeWald RL. Splenic injury complicating the anterior thoraco-abdominal surgical approach for scoliosis. *J Bone Joint Surg Am* 1985;65:396-7.
  32. McAfee PC. Complications of anterior approaches to the thoracolumbar spine: Emphasis on Kaneda instrumentation. *Clin Orthop Relat Res* 1994;306:110-9.
  33. Nakai S, Zielke K. Chylothorax: A rare complication after anterior and posterior spinal correction: Report on six cases. *Spine* 1986;11:830-3.
  34. Weis JC, Betz RR, Clements DH III, et al. Prevalence of perioperative complications after anterior spinal fusion for patients with idiopathic scoliosis. *J Spinal Disord* 1997;10:371-5.
  35. Burd TA, Pawelek L, Lenke LG. Upper extremity functional assessment after anterior spinal fusion via thoracotomy for adolescent idiopathic scoliosis. *Spine* 2002;27:65-71.
  36. Suk S, Kim JH, Lee SM, et al. Anterior-posterior surgery versus posterior closing wedge osteotomy in posttraumatic kyphosis with neurologic compromised osteoporotic fracture. *Spine* 2003;28:2170-5.
  37. Smith-Peterson MN, Larson CB, Aufranc OE. Osteotomy of the spine for correction of flexion deformity in rheumatoid arthritis. *J Bone Joint Surg Am* 1945;27:1-11.
  38. Thomasen E. Vertebral osteotomy for correction of kyphosis in ankylosing spondylitis. *Clin Orthop Relat Res* 1985;194:142-52.
  39. Saita K, Hoshino Y, Kikkawa I, et al. Posterior spinal shortening for paraplegia after vertebral collapse caused by osteoporosis. *Spine* 2000;25:2832-5.
  40. Leatherman KD, Dickson RA. Two-staged corrective surgery for congenital deformities of the spine. *J Bone Joint Surg Br* 1979;61:324-8.
  41. Lehmer SM, Keppler L, Buscup RS, et al. Posterior transvertebral osteotomy for adult thoracolumbar kyphosis. *Spine* 1994;19:2060-7.
  42. Berven SH, Deviren V, Smith JA, et al. Management of fixed sagittal plane deformities. *Spine* 2001;26:2036-43.
  43. Bradford DS, Ganjavian S, Antonious D, et al. Anterior strut-grafting for the treatment of kyphosis. *J Bone Joint Surg Am* 1982;64:680-90.
  44. Hu SS. Internal fixation in the osteoporotic spine. *Spine* 1997;22:435-8S.
  45. Etebar S, Cahill DW. Risk factors for adjacent-segment failure following lumbar fixation with rigid instrumentation for degenerative instability. *J Neurosurg* 1999;90:163-9.
  46. Havorson TL, Kelly LA, Thomas KA, et al. Effects of bone mineral density on pedicle screw fixation. *Spine* 1994;19:2415-20.
  47. Okuyama K, Sato K, Abe E, et al. Stability of transpedicle screwing for the osteoporotic spine: An in vitro study of the mechanical stability. *Spine* 1993;18:2240-5.
  48. Soshi S, Shiba R, Kondo H, et al. An experimental study on transpedicular screw fixation in relation to osteoporosis of the lumbar spine. *Spine* 1991;16:1335-41.
  49. Wu SS, Hwa SY, Lin LC, et al. Management of rigid post-traumatic kyphosis. *Spine* 1996;21:2260-7.
  50. Mckiernan F, Jensen R, Faciszewski T. The dynamic mobility of vertebral compression fractures. *J Bone Miner Res* 2003;18:24-9.
  51. Mckiernan F, Jensen R, Faciszewski T. Intravertebral cleft in osteoporotic compression fractures. *Arthritis Rheum* 2003;48:1414-9.
  52. Faciszewski T, Mckiernan F. Calling all vertebral fracture, classification of vertebral compression fractures: A consensus for comparison of treatment and outcome. *J Bone Miner Res* 2002;17:185-91.