

Posterior Correction and Fixation Without Anterior Fusion for Pseudarthrosis With Kyphotic Deformity in Ankylosing Spondylitis

Kao-Wha Chang, MD, Min-Yu Tu, MD, Hsin-Hsiung Huang, MD, Hung-Chang Chen, MD, Ying-Yu Chen, MD, and Chien-Chung Lin, MD

Study Design. Retrospective review.

Objective. To assess the effectiveness of posterior correction and fixation without anterior fusion for pseudarthrosis with kyphosis in patients with ankylosing spondylitis.

Summary of Background Data. Anterior fusion is the current surgical treatment for pseudarthrosis with kyphosis in ankylosing spondylitis. The unique characteristic in ankylosing spondylitis is the superior ability to bridge and fuse the large anterior opening-wedge gap created by posterior osteotomy to correct the kyphosis without anterior fusion after the osteotomy site is adequately fixed. This ability may persist even if pseudarthrosis is present.

Methods. A total of 30 consecutive patients with ankylosing spondylitis (mean age 41.7 years, range 29–55) underwent posterior correction and fixation without anterior fusion to treat pseudarthrosis with kyphosis. Mean follow-up was 4.7 years (range 2.2–9.1). Radiographic and clinical results and complications were assessed.

Results. Local kyphosis was substantially corrected from 45.5° (range 37°–68°) to 7.5° (0°–14°), with a mean correction of 38°. All patients had no evidence of nonunion on x-ray at the level of the pseudarthrosis at final follow-up. None had a notable loss of correction. No major complication occurred. There were 3 patients with neurologic deficits who had postoperative improvement.

Conclusion. Posterior correction and fixation is effective for treating pseudarthrosis with kyphosis in ankylosing spondylitis. No anterior fusion procedure was necessary.

Key words: anterior fusion, posterior osteotomy, pseudarthrosis, superior fusion ability. **Spine** 2006;31: E408–E413

In ankylosing spondylitis, the spine is vulnerable to trauma because of osteopenia and spinal rigidity. Relatively limited trauma may cause fractures, which are through the bone, and ligamentous disruptions through the disc space and facet joints.^{1,2} These fractures may not heal, and pseudarthrosis may form.^{1–5} A pseudoar-

throtic lesion can be a disco-vertebral lesion at the disco-vertebral junction or a destructive vertebral lesion within a vertebral body and is accompanied with a posterior weakness, consisting of either a nonunion fracture of the posterior elements or mobile facet joints.^{1,5–7} Pseudarthrosis may cause deformity, severe back pain, and neurologic sequelae. Appropriate treatment depends on the patient's clinical appreciation, and accurate radiologic diagnosis of the complication and its extent and severity.

Anterior fusion is the current surgical procedure for pseudarthrosis in patients with ankylosing spondylitis. Most surgeons believe that anterior fusion allows them direct access to the anterior lesion and that it is biomechanically superior to posterior fusion in a kyphotic spine.^{7–9} Focal kyphosis can be corrected through an anterior approach, but not the global kyphosis in the thoracic spine and loss of lumbar lordosis in patients with ankylosing spondylitis. Most surgeons use a combined approach for treatment of pseudarthrosis and correction of kyphotic deformity in patients with ankylosing spondylitis.

Reviewing our experience in more than 200 patients with surgically treated ankylosing spondylitis kyphosis,^{10,11} we noted superior fusion ability without the need for anterior fusion (*i.e.*, satisfactory fusion of the large anterior gap was almost always achieved after the kyphosis was corrected with posterior opening-wedge osteotomy but without additional anterior fusion after the osteotomy site was adequately fixed). We believe that this method can also successfully treat pseudarthrosis with kyphotic deformity in patients with ankylosing spondylitis. Therefore, the purpose of this study was to evaluate the effectiveness of posterior correction and fixation without anterior fusion in 30 patients with ankylosing spondylitis, pseudarthrosis, and kyphotic deformity. To our knowledge, this method of treatment has not been described.

Materials and Methods

Between 1995 and 2003, 37 patients with ankylosing spondylitis and pseudarthrosis, as confirmed with established clinical and radiographic criteria,¹² were examined at our institution. There were 7 patients who had a more or less straight spine who were excluded. A total of 30 patients presented with round thoracolumbar kyphosis of various degrees with the apex of kyphosis at the level of the pseudarthrosis. The patients were comprised of 26 men and 4 women, with a mean age of 41.7 years (range 29–55).

From the Taiwan Spine Center and Department of Orthopaedic Surgery, Armed Forces Taichung General Hospital, Taiwan, Republic of China.

Acknowledgment date: July 21, 2005. First revision date: October 6, 2005. Second revision date: November 11, 2005. Acceptance date: November 23, 2005.

The manuscript submitted does not contain information about medical device(s)/drug(s).

No funds were received in support of this work. No benefits in any form have been or will be received from a commercial party related directly or indirectly to the subject of this manuscript.

Address correspondence and reprint requests to Kao-Wha Chang, MD, Taiwan Spine Center and Department of Orthopaedic Surgery, Armed Forces Taichung General Hospital, Taiwan. No. 348, Sec. 2, Chung-Shan Road, Taiping City, Taichung Hsein, Taiwan, Republic of China; E-mail: iscspine@ms45.url.com.tw

Mean follow-up was 4.7 years (range 2.2–9.1). The period between the onset of symptoms of ankylosing spondylitis and radiographic detection of pseudoarthrosis was 2 to more than 20 years. All patients complained of back pain and progression of the kyphotic deformity. In all patients, these complaints were related to trauma.

Standing anteroposterior and lateral radiographs were obtained before and immediately after surgery, and at last follow-up. Radiographs were evaluated for pseudoarthrotic lesions, local kyphosis at the apex of kyphosis, and postoperative fusion (Table 1). Local kyphosis in the apical region was estimated as the angle between lines drawn from the posterior aspect of the 2 normal cranial vertebral bodies and lines drawn from the posterior aspect of 2 normal caudal vertebral bodies (Figures 1, 2).¹³

Magnetic resonance imaging (MRI) or computerized tomography (CT) was used to identify cord compression. There were 17 patients who had canal encroachment in which the anteroposterior diameter of the spinal canal was markedly decreased. All had encroachment caused by posterior extradural tissue resulting from inflammation of the ligamentum flavum and facet joints, as well as from callus formation on the fractures of the posterior elements. Of these patients, 2 had a neurologic deficit of Frankel grade C, and 1 patient, Frankel D. Of the 17 patients, 2 had small anterior encroachment caused by osteolysis of the anterior elements, with small osteophytic formation in addition to posterior encroachment (Table 1). However, these 2 patients did not have neurologic symptoms. Gallium scanning was used to differentiate pseudoarthrosis from infection. Table 2 shows that most of the pseudoarthrotic lesions were near the thoracolumbar junction, with the highest being at T9–T10 and the lowest at L2–L3.

All patients were treated with opening-wedge osteotomy at the level of pseudoarthrosis for correction and with pedicle screw instrumentation for fixation. Apart for manual osteoclasis, which was omitted because of the pseudoarthrosis, the technique of opening-wedge osteotomy was the same as that described in our previous reports.^{10,11} No anterior spinal fusion procedures were performed in any patient.

■ Results

The 3 patients with neurologic deficit had postoperative improvement. The 2 patients with Frankel grade C and

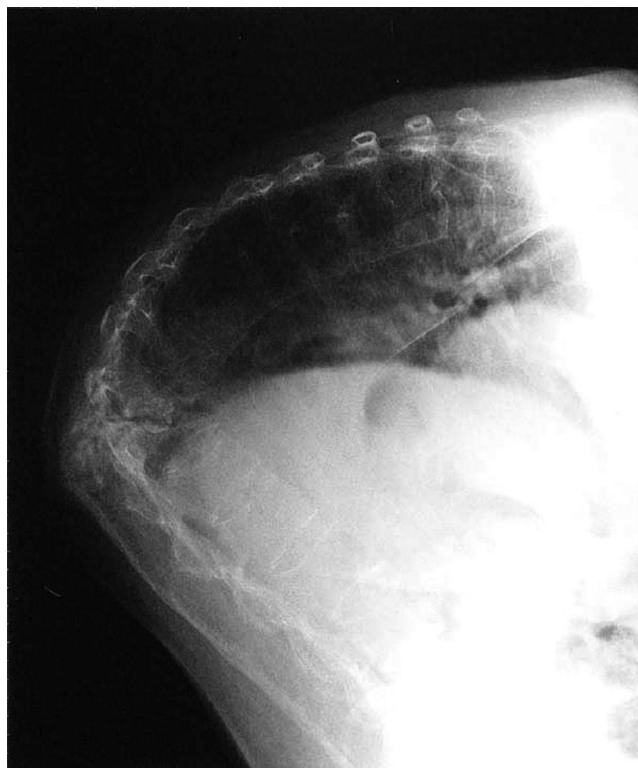

Figure 1. Typical pseudoarthrotic lesion with kyphosis in a patient with ankylosing spondylitis. Image shows an anterior extensive destructive lesion with nonunion fracture of the posterior elements of the affected segment at the kyphotic apex.

the 1 with Frankel grade D deficit before surgery had improvement to Frankel grade E with normal strength and sensation after surgery. In all patients, the anterior vertebral lesions were extensive destructive lesions, with a demonstrable weakness in the posterior elements of the affected segment (Figure 1). Local kyphosis was substantially corrected from 45.5° (range 37°–68°) to 7.5° (range 0°–14°), with a mean correction of 38° (Table 1). No patient had any notable loss of correction between discharge and final follow-up. There was no evidence of nonunion on x-ray at the level of pseudoarthrosis at final follow-up (Figures 2, 3).

No perioperative deaths or neurovascular complications occurred. Postoperative pneumonia developed in 1 patient, which was successfully treated with respiratory and antibiotic therapy. There was 1 superficial infection that was treated with debridement and antibiotics, and it resolved uneventfully.

■ Discussion

A pseudoarthrotic lesion in ankylosing spondylitis can be a disco-vertebral lesion at the disco-vertebral junction or a destructive vertebral lesion within a vertebral body, depending on if the initial injury is disruption of a disc space or fracture through a vertebral body.^{1,5–7} Andersson¹⁴ first described disco-vertebral destructive lesions or spondylodiscitis occurring in ankylosing spondylitis in 1937. Cawley *et al*⁹ classified these lesions into localized central

Table 1. Radiographic Data

	No. Patients	Mean (range)
Types of Lesions		
Local kyphosis	30	
Pseudoarthrotic lesion		
Extensive disco-vertebral lesion	30	
Fracture in the posterior element	30	
Canal encroachment		
Posterior encroachment	17	
Anterior encroachment	2	
Degree of kyphosis		
Local kyphosis		
Preoperative		45.5° (37°–68°)
Immediate postoperative		7.5° (0°–14°)
Final follow-up		9.5° (1°–16°)
Correction		38° (31°–58°)
Loss of correction		2.0° (1°–6°)

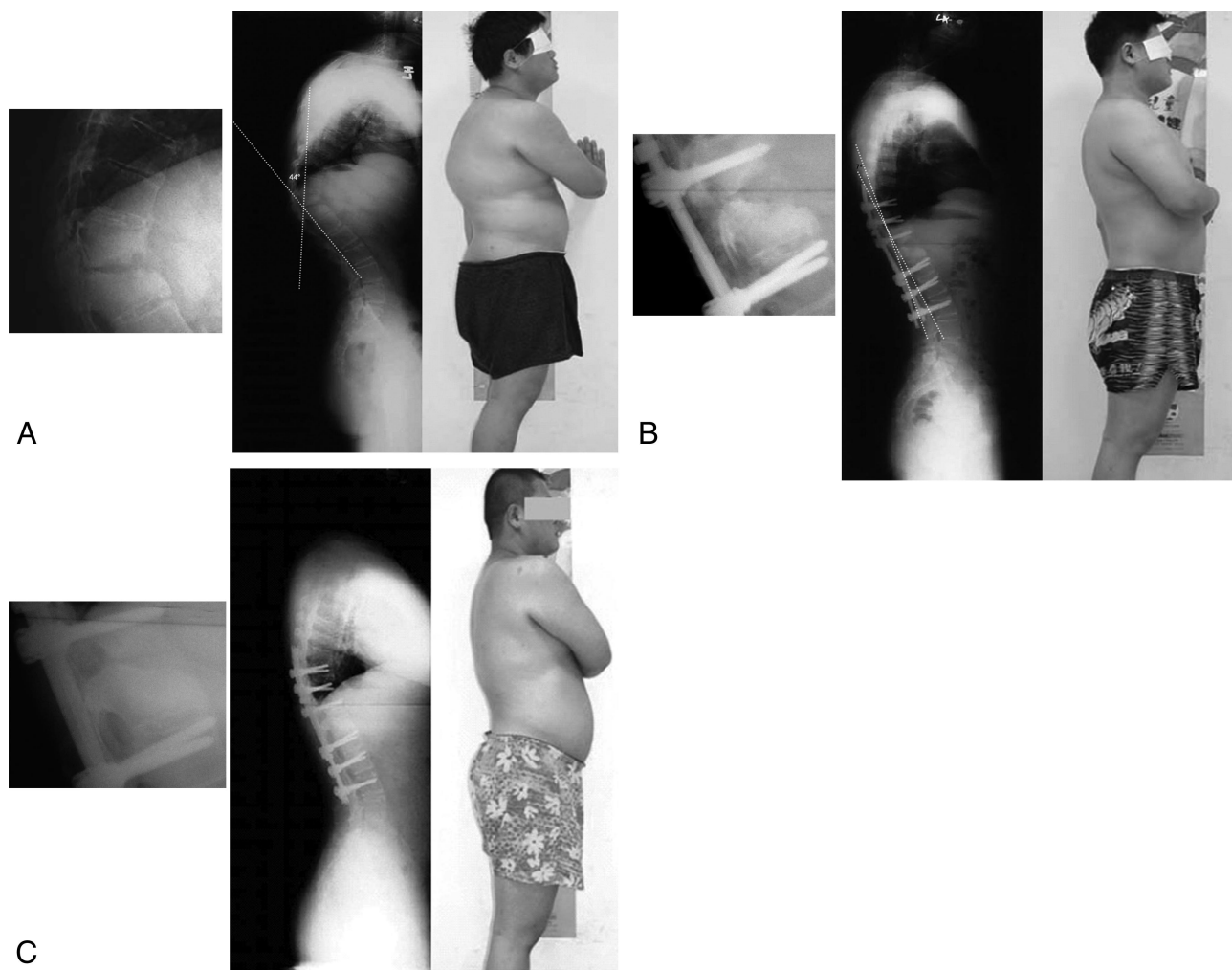


Figure 2. A 33-year-old man with painful, round kyphosis. **A**, Apex at T11–T12 was caused by ankylosing spondylitis with pseudarthrosis. Local kyphosis is 44°. **B**, Two months after surgery, normal sagittal alignment is restored. Local kyphosis is 7°. **C**, At 2 years, no evidence of nonunion on x-ray and no loss of correction.

or peripheral disco-vertebral lesions, and extensive central and peripheral disco-vertebral lesions.

Whether inflammatory rather than mechanical factors play a role in the development of destructive intervertebral disc lesions has been debated.¹⁵ Localized lesions may occur, even early in the course of ankylosing spondylitis and without a preceding trauma; this observation supports an inflammatory mechanism. Extensive disco-vertebral destruction occurs almost exclusively in patients with advanced ankylosis, and this is often preceded by trauma, which may be relatively trivial.⁹ Extensive vertebral lesions could occur within the body of a verte-

bra, if the initial injury is fracture through a vertebral body. Fang *et al*⁷ recommended that all such extensive destructive lesions be simply termed spinal pseudarthrosis. In all our patients, the anterior vertebral lesions were extensive destructive lesions with demonstrable weakness in the posterior elements of the affected segment, and the onsets were all related to injury.

Spinal pseudarthrosis is radiologically distinct as a condition with anterior-element osteolysis in the presence of a posterior-element weak link. It is clinically distinct as a lesion of treatment importance with respect to the persistent and painful symptoms, progression of pre-existing kyphotic deformity, likelihood of progressive myelopathy,¹⁶ and surgical implications. Most surgeons recommended anterior fusion for pseudarthrosis with kyphotic deformity in patients with ankylosing spondylitis. They believe that anterior fusion allows them direct access to the anterior lesion and that it is biomechanically superior to posterior fusion in a kyphotic spine.^{7–9} The thoracolumbar region in patients with ankylosing spondylitis and kyphosis contains the segments most sus-

Table 2. Level Distribution of Pseudoarthrosis

Level	No. Lesions (n = 30)
T9–T10	1
T10–T11	3
T11–T12	13
T12–L1	10
L1–L2	2
L2–L3	1

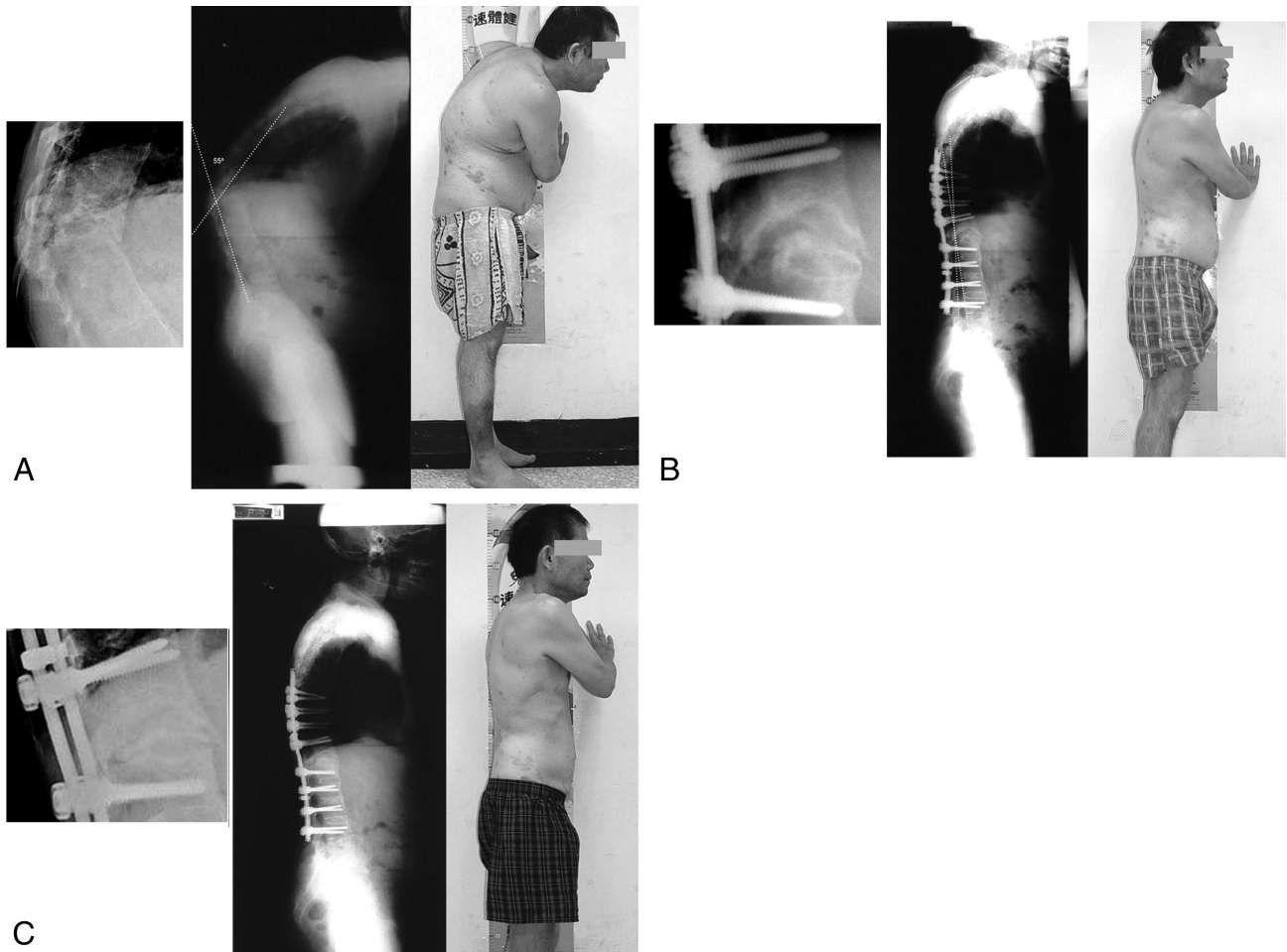


Figure 3. A 47-year-old man with progressive, painful round kyphosis. **A**, Apex at T11–T12 was caused by ankylosing spondylitis with pseudarthrosis. Local kyphosis is 55° . **B**, At 2 months after surgery, normal sagittal alignment is restored. Local kyphosis is 6° . **C**, At 2 years, no evidence of nonunion on x-ray and no loss of correction.

ceptible to shearing or distraction. A fracture is most likely to occur at such a site of concentrated stress, and the resultant long-level arm of motion makes spontaneous healing difficult.

Pseudarthrosis most commonly occurs at the thoracolumbar region of T11–L1, as observed in 77% of our patients. Anterior surgery around the thoracolumbar junction usually requires the surgeon to enter the chest and detach the diaphragm; however, older patients cannot always tolerate this approach. In addition, with an anterior procedure alone, correction of the kyphotic deformity in ankylosing spondylitis is impossible and dangerous because of the possible neurologic complications.

The unique characteristic of ankylosing spondylitis is its superior fusion ability. According to our work, the large anterior opening wedge created with posterior osteotomy to correct the thoracolumbar kyphosis can almost always achieve solid fusion without an anterior fusion procedure after the osteotomy site is adequately fixed.^{10,11} We believe this is also the case in the presence of pseudarthrosis. We observed no evidence of nonunion on x-ray at all anterior gaps created in the pseudarthrosis during posterior correction at final follow-up; this finding proves the reliability of this method.

We believe that fixation is the most important factor in achieving fusion in the ankylosing spondylitis spine. The sequence of progression in ankylosing spondylitis is from an ankylosing spine to a calcified bamboo spine. The former is actually a kind of biologic fixation. All the soft tissue among the bones, including ligaments, discs, and joints, gradually fuse after biologic fixation. Our previous studies^{10,11} and this study showed that no evidence of nonunion on x-ray was found at all gaps among vertebral bodies created by posterior opening-wedge osteotomy after the osteotomy site was rigidly fixed using pedicle screws. Of course, the correction of kyphosis to reduce shearing and distraction forces, and improve the biomechanical environment for fusion might be other important factors for obtaining fusion.

We used opening-wedge osteotomy at the level of pseudarthrosis to correct the deformity for 2 reasons. First, the use of closing-wedge osteotomy (a spine-shortening procedure) to achieve a mean kyphotic correction of 38° in the lower thoracic or thoracolumbar spine would be dangerous in terms of spinal shortening and possible cord compression and damage.¹⁷ Second, the vertebral column at the site of the pseudarthrosis was already fractured; therefore, the procedure of manual osteoclasis could be omitted.

Thus, the procedures of opening-wedge osteotomy were simplified and easily accomplished.

As Kanefield *et al*¹⁸ pointed out, fractures in ankylosing spondylitis are easily overlooked, and nonunion occurs with a resultant buildup of fibrous pseudarthrosis tissue. This buildup progressively compresses the spinal cord and nerve roots, producing a central neurogenic type of pain that may radiate to the legs, and may or may not be associated with paralysis of the bladder and extremities. Patients with these symptoms may require anterolateral decompression and fusion to recover function, gain stability, and relieve pain.

We used MRI or CT to identify cord compression. MRI is valuable in this assessment. However, kyphosis related to ankylosing spondylitis is sometimes severe and leads to difficulties in positioning the patient in the MRI unit. The spine may be some distance from the coil, which often causes suboptimal visualization of the region of interest. In such instances, we have found CT in the lateral decubitus position to be useful. We apply sagittal reconstruction as necessary, although certainly the detail of the vascular fibrous tissue is not visualized as clearly as it is on MRI.

There were 17 patients who had canal encroachment, and 3 had neurologic symptoms, but none of these patients had encroachment caused by anterior fibrous pseudarthrosis tissue, as Kanefield *et al*¹⁸ described. Only 2 of the 17 patients had small anterior osteophytes, but they had no neurologic symptoms. All 17 patients had encroachment caused by posterior extradural tissue, including hypertrophy of the ligamentum flavum and facet joints, and callus formation on posterior-element fracture, which can be easily removed with posterior opening-wedge procedures. The 3 patients with neurologic deficits recovered function after posterior opening-wedge osteotomy without anterior decompression. Correction of kyphosis, which results in posterior migration of the spinal cord away from the apex to diminish tension on spinal cord,¹⁹ and fixation of the unstable ankylosing spondylitis spine caused by pseudarthrosis may be other possible mechanisms for neurologic recovery.

We used to perform the technique¹³ described in this study to measure local kyphosis for fractures that result in angular kyphosis within a round kyphosis. Based on the following 3 reasons, we only measure local kyphosis rather than local and global kyphosis to evaluate correction and loss of correction at the site of osteotomy and pseudarthrosis as evidence of nonunion at that site. First, in our previous studies,^{10,13} correction of local kyphosis correlates well with correction of global kyphosis. Improvement of local sagittal alignment represents a positive effect on global alignment and balance. Second, according to the report by McMaster and Coventry²⁰ and our study,¹⁰ the “disease” ankylosing spondylitis at sites other than the osteotomy site could allow for increased flexion deformity and detract from the initial correction of global alignment and balance during follow-up. In other words, the loss of correction of

global kyphosis does not mean the loss of correction at the site of osteotomy and pseudarthrosis, and cannot be evidence of nonunion at that site.

Third, the purpose of this study is not to show how much correction can be obtained with opening-wedge osteotomy. Opening-wedge osteotomy enabling substantial correction for ankylosing spondylitis kyphosis has been shown in numerous reports, including ours.¹⁰ This study tries to show that a preexisting pseudarthrosis at the site of osteotomy can obtain fusion by the superior fusion ability in patients with ankylosing spondylitis and fixation without anterior fusion procedures. No notable loss of any correction at the site of osteotomy and pseudarthrosis during follow-up can be an important piece of evidence of union at that site. In summary, because of its superior fusion ability in ankylosing spondylitis, posterior opening-wedge osteotomy and fixation can successfully treat pseudarthrosis with kyphosis in patients with ankylosing spondylitis. Anterior fusion procedures were not required to achieve fusion in our patients.

■ Key Points

- Anterior fusion is the current surgical treatment for pseudarthrosis with kyphosis in patients with ankylosing spondylitis.
- The unique characteristic in ankylosing spondylitis is its superior fusion ability.
- Pseudarthrosis with kyphosis in ankylosing spondylitis can be effectively treated with posterior correction and fixation without anterior fusion.

References

1. Chan FL, Ho EKW, Chau EMT. Spinal pseudoarthrosis complicating ankylosing spondylitis: Comparison of CT and conventional tomography. *AJR Am J Roentgenol* 1988;150:611–9.
2. Gelman MI, Umber JS. Fractures of the thoracolumbar spine in ankylosing spondylitis. *AJR Am J Roentgenol* 1978;130:485–93.
3. Dilorio G, Sundaram M. Fracture with pseudoarthrosis in ankylosing spondylitis. *Orthopedics* 1990;13:118–25.
4. Hunter T, Dubo HIC. Spinal fractures complicating ankylosing spondylitis. *Arthritis Rheum* 1983;26:751–9.
5. Pastershank SP, Resnick D. Pseudoarthrosis in ankylosing spondylitis. *J Can Assoc Radiol* 1980;31:234–42.
6. Hung CT, Yng ST, Han NT. Pseudoarthrosis and pseudopseudoarthrosis of ankylosing spondylitis: Report of 2 cases. *Zhonghua Yi Xue Za Zhi (Taipei)* 1992;50:500–3.
7. Fang D, Leong JCY, Ho E. Spinal pseudoarthrosis in ankylosing spondylitis. *J Bone Joint Surg* 1988;70B:443–7.
8. Yan AC, Chan RNW. Stress fracture of the fused lumbo-dorsal spine in ankylosing spondylitis. *J Bone Joint Surg* 1974;56B:681–7.
9. Cawley MID, Chalmers TM, Kellgren JH. Destructive lesions of vertebral bodies in ankylosing spondylitis. *Ann Rheum Dis* 1972;31:355–8.
10. Chang KW, Chen YY, Lin CC. Closing wedge osteotomy VS opening wedge osteotomy in ankylosing spondylitis with thoracolumbar kyphosis. *Spine* 2005;30:1584–93.
11. Chang KW, Chen YY, Lin CC. Sagittal translation in opening wedge osteotomy for correction of thoracolumbar kyphosis in ankylosing spondylitis. *Spine*. In press.
12. Chan FL, Ho EKW, Fang D. Spinal pseudoarthrosis in ankylosing spondylitis. *Acta Radiol* 1987;28:383–8.
13. Chang KW, Chen YY, Lin CC, et al. Apical lordosating osteotomy and

- minimal segment fixation for the treatment of thoracic or thoracolumbar osteoporotic kyphosis. *Spine* 2005;30:1674–81.
14. Andersson O. Röntgenbilderna vid spondylarthritis ankylopoetica. *Nord Med Tidsskr* 1937;14:2002–2.
 15. Rasker JJ, Prevo RL, Lanting PJH. Spondylodiscitis in ankylosing spondylitis. Inflammation or trauma? *Scand J Rheumatol* 1996;25:52–7.
 16. Good AE, Keller TS, Weatherbee L. Spinal cord block with a destructive lesion of the dorsal spine in ankylosing spondylitis. *Arthritis Rheum* 1982;25:218–25.
 17. Kawahara N, Tomita K, Kobayashi T. Influence of acute shortening on the spinal cord. *Spine* 2005;30:613–20.
 18. Kanefield DG, Mullins BP, Freehafer AA, et al. Destructive lesions of the spine in rheumatoid spondylitis. *J Bone Joint Surg* 1969;51A:1369–75.
 19. Batzdorf U, Batzdorf A. Analysis of cervical spine curvature in patients with cervical spondylosis. *Neurosurgery* 1988;22:827–36.
 20. McMaster MJ, Coventry MB. Spinal osteotomy in ankylosing spondylitis: Technique, complications, and long-term results. *Mayo Clin Proc* 1973;48:476–87.